

## Hepatoprotective effects of walnut oil and *Caralluma tuberculata* against paracetamol in experimentally induced liver toxicity in mice

Sana<sup>1</sup>, Shafiq ur Rahman<sup>2</sup>, Muhammad Zahid<sup>1</sup>✉, Ayaz Ali Khan<sup>3</sup>, Tariq Aziz<sup>4</sup>✉, Zafar Iqbal<sup>5</sup>, Waqar Ali<sup>3</sup>, Fehmida Farid Khan<sup>6</sup>, Sumbal Jamil<sup>7</sup>, Muhammad Shahzad<sup>8</sup>, Metab Alharbi<sup>9</sup> and Abdulrahman Alshammari<sup>9</sup>

<sup>1</sup>Department of Zoology, Islamia College University Peshawar, Pakistan; <sup>2</sup>Department of Environmental Sciences, Shaheed Benazir Bhutto University, Sheringal Dir Upper, Pakistan; <sup>3</sup>Department of Biotechnology, University of Malakand, Chakdara, 18800, Pakistan; <sup>4</sup>School of Food & Biological Engineering, Jiangsu University, Zhenjiang China; <sup>5</sup>Institute of Nursing Sciences, Khyber Medical University, Peshawar, Pakistan; <sup>6</sup>Department of Molecular Biology, Shaheed Zulfiqar Ali Bhutto Medical University Islamabad, Pakistan; <sup>7</sup>Rehman Medical Institute Peshawar, Khyber Pakhtunkhwa, Pakistan; <sup>8</sup>School of Biological Sciences, Health and Life Sciences Building, University of Reading, Reading RG6 6AX, UK; <sup>9</sup>Department of Pharmacology and Toxicology, College of Pharmacy, King Saud University, Riyadh 11451, Saudi Arabia

Walnut Oil and *Caralluma* are edible and form part of the traditional medicine system in many countries. These are frequently used in traditional medicine as remedies to relieve a wide range of illnesses and health problems. Walnut Oil and *Caralluma* species have demonstrated anti-inflammatory, anti-nociceptive, antidiabetic, hepatoprotective, gastric mucosa protecting, antimalarial, antioxidant, anti-trypanosomal, appetite suppressant and cytotoxic activities. The current study was planned to study the impacts of 21 days' oral administration of walnut oil and methanolic extract of *Caralluma tuberculata* on the levels of some liver-associated parameters and hematological parameters in paracetamol intoxicated mice. It was observed that paracetamol intoxication resulted in a considerable rise in serum ALT, cholesterol, triglycerides, Creatinine, and urea levels while a decrease in HDL level in comparison to mice normal control group ( $P < 0.05$ ). Serum ALT, cholesterol, triglycerides, creatinine, and urea levels of mice that were administered with walnut oil and methanolic extract of *C. tuberculata* at the doses of (1 ml/kg, 2 ml/kg and 3 ml/kg body weight) were significantly lower when compared to toxic control mice group ( $P < 0.05$ ). While HDL level was significantly increased. The significant reduction had also been observed in the levels of serum parameters of mice group, which received standard hepatoprotective drug i.e., vitamin C, at the dose of 8 mg/kg body weight ( $P < 0.05$ ). Based on these results, it was evident that liver toxicity caused by the paracetamol administration has recovered toward the normal range by the walnut oil and *C. tuberculata* extract. Therefore, the present study revealed that (walnut oil and *C. tuberculata*) exhibit hepatoprotective activities in paracetamol intoxicated mice.

**Keywords:** hepatoprotective, walnut oil, *C. tuberculata*, histopathology, ALT

**Received:** 06 June, 2022; **revised:** 21 September, 2022; **accepted:** 04 October, 2022; **available on-line:** 24 October, 2022

✉e-mail: [drmzahid@icp.edu.pk](mailto:drmzahid@icp.edu.pk) (MZ); [iwockd@gmail.com](mailto:iwockd@gmail.com) (TA)

**Acknowledgments of Financial Support:** The authors greatly acknowledge and express their gratitude to the Researchers Supporting Project number (RSP2022R491), King Saud University, Riyadh, Saudi Arabia.

**Abbreviations:** ALT, alanine transaminase; AST, aspartate transaminase; CBC, complete blood count; HDL, high density lipoproteins; LDL, low density lipoprotein; PLT, platelets count

### INTRODUCTION:

The liver is the prime organ in the human body that helps in maintaining metabolic and physiologic homeostasis. It plays a central and important role in many metabolic pathways especially those related to growth and development, fighting off diseases, production and supply of nutrients and energy, metabolism of proteins, carbohydrates and fats, bile secretion and storage of vitamins (Ouassou *et al.*, 2021; Sami *et al.*, 2019; Tafere *et al.*, 2019; Ugwu & Suru 2021; Wahid *et al.*, 2016). Furthermore, the liver is also a crucially important organ in drug metabolism and protecting humans against the harmful impact of many toxic agents. These toxic exogenous (toxins, alcohol, environmental pollutants, viruses, and xenobiotic substances) or endogenous (autoimmune diseases) agents are a major risk factor for hepatic injury leading to hepatitis fibrosis, cirrhosis, cancer, and other diseases of the liver (Maev *et al.*, 2014; Real *et al.*, 2019; El-Hadary & Ramadan Hassanien, 2016). Hepatic damage, due to any reason, greatly hampers the normal functioning of many metabolic processes. In the majority of the cases, the damage is obvious from alteration in alanine transaminase (ALT) and aspartate transaminase (AST); the enzymes found in different body tissues and serum but originating from parenchymal cells of the liver (Kannan *et al.*, 2013).

Only some conventional drug remedies are available to treat and improve hepatic functions, but they are also associated with hepatic injury when overdosed (Gagliano *et al.*, 2007). These drugs can induce hepato-toxicity resulting in raised ALT and AST and associated liver damage. Of these, Acetaminophen (N-acetyl-p-aminophenol, paracetamol), an antipyretic and painkiller drug is the most common hepatotoxic agent. The drug act by selective suppression of the Cox-3 enzyme pathway in the spinal cord and brain thus reducing pain and fever (Chandrasekharan *et al.*, 2002). Paracetamol is metabolized by the liver and then excreted through the kidneys (Kannan *et al.*, 2013). Paracetamol is one of the most commonly available, over-the-counter drugs that is administered by oral, intravenous injection or rectal route to relieve pain and fever (Pathan *et al.*, 2014). In normal dosage, the drug is safe, but an overdose can induce liver damage, nephrotoxicity, extrahepatic lesion and even death (Bhattacharyya *et al.*, 2003; Darbar *et al.*, 2011). Research

evidence suggests that almost 40% of drug-associated liver disorders are associated with paracetamol overdose (Omotayo *et al.*, 2015) for instance, chronic liver diseases and drug-induced hepatic injuries are among the top ten leading causes of death worldwide (Harsha *et al.*, 2021; Saleem *et al.*, 2010), thereby requiring remedies that are safe and effective. In this context, natural herbal preparations offer a promising alternative that is not only effective to treat and prevent liver damage but also safe and free of side effects.

Pakistan is home to a rich and diverse flora consisting of almost 5700 species. Among these, around 2000 species are believed to possess important pharmacologic activities against various illnesses and thus constitute a large group of medicinally important plants (Ullah, 2017). Walnut (*Juglans juglandaceae*) is a commonly grown tree in mountainous terrains of the world including Pakistan. Different parts of this have traditionally been used for medicinal purposes owing to its antioxidant, antimicrobial, anti-inflammatory, immune-modulatory and wound healing activities. The most important part of the tree is the walnut fruit, consisting of an outer green shell cover or husk, the middle shell which after cracking releases the kernel. Kernel, the nutrient-rich part of the fruit is commonly used as a food supplement and cosmetic products across the world (Pereira *et al.*, 2007; Stampar *et al.*, 2006; Britton *et al.*, 2009). Similarly, walnut tree leaves are a rich source of different compounds possessing health promoting activities and therefore, commonly used in folk medicines for the curing of venous insufficiency, inflammation of skin and ulcers (Eidi *et al.*, 2013). Recent research studies, both in human and animal models have also reported antidiabetic, antioxidant, and lipid-lowering effects of the leaf extracts from walnut tree (Mollica *et al.*, 2017). Flavonoids PUFAs are the main bioactive compounds isolated from the leaves, with proven beneficial activities as reported previously (Panth *et al.*, 2016; Carey *et al.*, 2013).

Correspondingly, *C. tuberculata*, a family member of Asclepiadaceae (milkweed family), is an edible, juicy, leafless stiff plant that commonly grows in dry, undomesticated regions of Pakistan and other countries such as Saudi Arabia, Nigeria, and Iran (Mudrikah *et al.*, 2015). *C. tuberculata* is extensively found in the mountainous areas of Khyber Pakhtunkhwa province of Pakistan, where it is called Pamankay in the local Pashto language. The plant has commonly known for its ethnomedicinal applications including the treatment of dysentery, jaundice, constipation, stomach pain, blood purification, liver ailments and hypertension (Baig *et al.*, 2021; Delaviz *et al.*, 2017; Adnan *et al.*, 2014). The disease prevention and health-promoting effects of the plant are primarily attributed to its antioxidant, antibacterial (Mudrikah *et al.*, 2015), hypolipidemic, anti-hyperglycemic (Abdel-Sattar *et al.*, 2011; Essam *et al.*, 2011), and *in vitro* anticancer potentials (Waheed *et al.*, 2011). The plant has been shown to contain many bioactive secondary metabolites including steroids, reducing sugars, terpenoids, beta cyanin, tannins and amino acids. Taking the above medicinally important activities into account, the current study was designed to assess hepatoprotective effects of walnut oil and *C. tuberculata* extract in paracetamol-induced liver damage in mice.

## MATERIALS AND METHODS

### Preparation of plant extracts and walnut oil

*C. tuberculata* plants and walnut fruits were purchased from a local market in Dir (Lower), Pakistan. The plants

were allowed to dry in shade for one month followed by mechanical grinding to obtain a fine powder. The powder (800 g) was soaked in 90% methanol at room temperature and after 10 days, the extract was filtered using filter paper. The filtrate was collected and vaporized using Rotary Evaporator. The methanol was evaporated at a temperature of 70°C in a water bath and a pressure of 50 Pa, the concentrated extract was obtained. The extract was then kept at room temperature. Walnuts were taken and the shells were removed, endosperm was collected and processed through the cold pressing method to extract the oil.

### Experimental animals

One month-old, healthy, Albino mice were obtained from the National Institute of Health Islamabad and kept in the Bio Park of the Biotechnology Department, University of Malakand. Mice were housed in polypropylene cages, each containing 8–10 animals, sustained under standard conditions and provided the same dried food and water *ad libitum* until the day of experiments. Standard ethical guidelines regarding the care of the animal were followed. Ethical approval of the study was obtained from the ethics board of Islamia College University, Peshawar.

### Grouping and extract administration

Mice were randomly divided into nine different groups each containing 10 mice. The positive control group was intoxicated with 200 mg/kg body weight paracetamol while the negative control group only received normal feed and water *ad libitum*. Group A, B and C mice were intoxicated with paracetamol (200 mg/kg body weight) and fed with walnut oil at a dose of 1, 2 or 3 mL/kg body weight, respectively. Group D, E and F also receive the same paracetamol dose and *C. tuberculata* extract at a dose of 1, 2, 3 mL/kg body weight, respectively.

### Laboratory analysis

Complete blood count (CBC) was done by Automatic Digital Machine (Sysmex Kx-21) for the assessment of Leucocytes, Neutrophils, Lymphocytes, Platelets count (PLT), Monocytes and Eosinophils count. Serum biochemical parameters such as total cholesterol, triglyceride, uric acid, creatinine, HDL, LDL and ALT were analyzed using Enzyme-linked immunosorbent assay (ELISA) following manufacturer instructions.

### Histopathological examination

Once the blood was collected, the mice were sacrificed. Mice livers were collected, cut into small pieces, and fixed in 10% formalin. After fixation, the specimens were dehydrated, then embedded in wax and sectioned into 5 µm thicknesses. The sections were then stained with eosin and Hemotoxillin. For slide preparation, the mice's liver was carried out in 10% formalin for 14 hours. For dehydration propanol was used in the percentage of 70% for 1 hour, 80% for 1 hour and 95% for 1 hour. After dehydration, de-alcoholization was done by xylene. Two types of xylenes were used namely xylene pure and xylene alcohol. This process was repeated three times. First, the specimen was taken in xylene alcohol for 1 hour, then in xylene pure for 1 hour and then again in xylene pure. This process removed all the alcohol from the specimen tissue. Parafast wax was used to remove xylene. These are embedded wax melted at

55°C. Then the L-Blocks which are made of alloy were taken and were cut into blocks with the help of a microtome (rotary microtome).

### Evaluation of hepatoprotective activity

Based on the paracetamol-induced liver damage method as described in various studies (Hussain *et al.*, 2014; Qadir *et al.*, 2014; Saleem *et al.*, 2014), the *in-vivo* hepatoprotective activity was assessed.

### Slide formation and its microscopic study

Staining was done in two steps i.e., slides were put in xylene, dilute for 1 hour and then put in xylene pure for 1 hour for the removal of waxes from the slides. Then they were put in propanol concentrated for 1 hour and again in propanol pure for another 1 hour, then in water for 30 minutes and shaken the slide. After that, they were then put in hematoxylin which started staining in fifteen minutes. Hematoxylin in nature is nucleophilic. They were put in water and then in acid alcohol. The stain was taken by all slides. With the help of acid al-

cohol, the stains were removed from those areas which were not needed. Then again, they were put into water to remove acid alcohol and then in ammonia water for 5 minutes which give a reddish color. Propanol was used again to attach with eosin to give reddish color easily, then again diluted propanol was used to remove eosin from slides except for staining areas. Xylene was used again to remove water and alcohol. Candabalsam and dpx (mixture of distyrene, plasticizer and xylene) were applied to the thin slice and then a cover slip was put to cover it. The slides were ready for microscopic examination. The slides were studied by an electric microscope model No. M 7000 D (SWIFT, Japan) and the pictures were captured by a digital camera of microscope DCM 130 (SWIFT, Japan) (USB 2.0) with a resolution of 1.3 M pixels which is commonly known as the CCT camera.

### Statistical analysis

All samples were measured in triplicate. Statistical analysis was carried out using one-way analysis of vari-

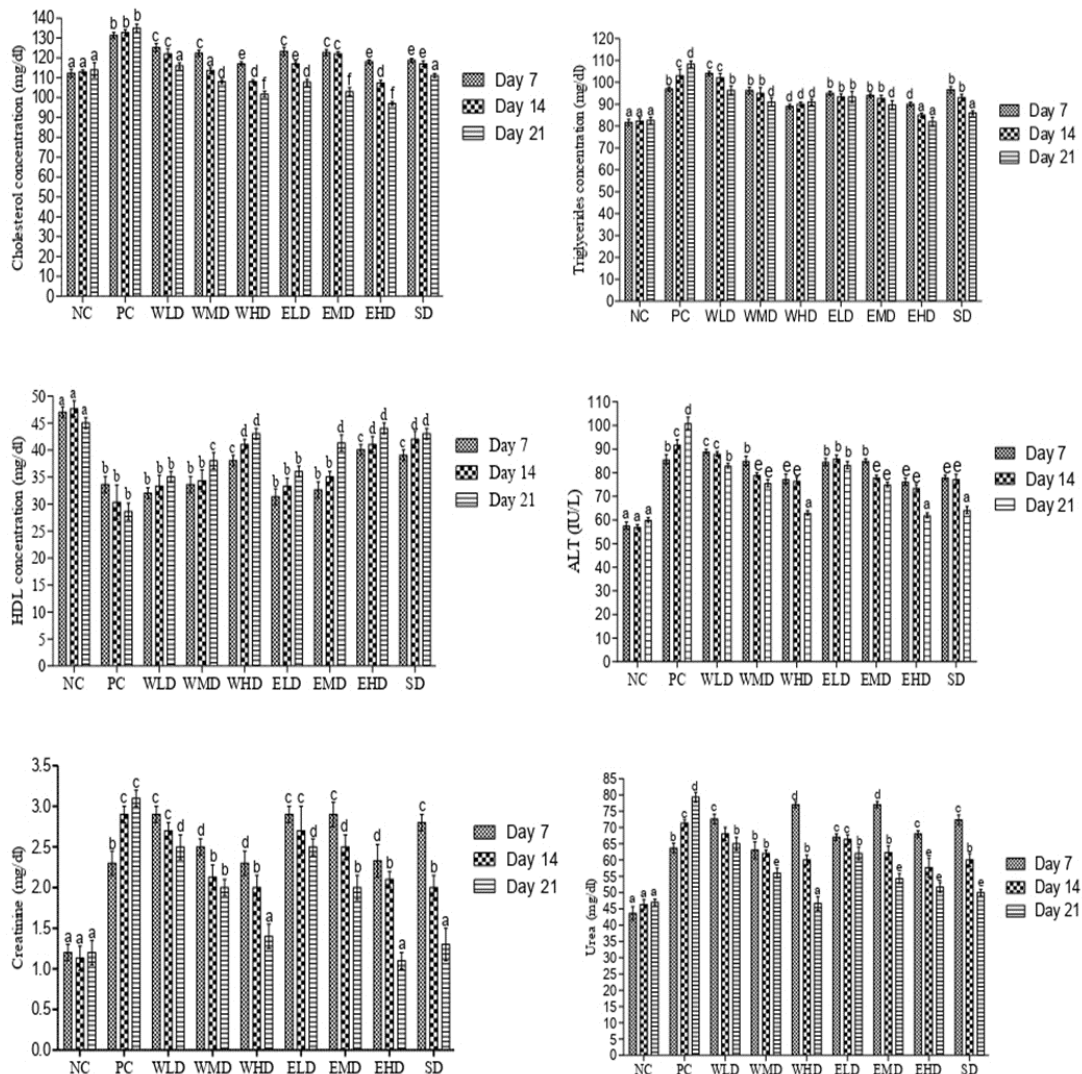


Figure 1. Biochemical parameters of different mice groups.

NC: Normal Control, PC: positive control, WLD: walnut oil with low dose group, WMD: walnut oil with medium dose group, WHD: walnut oil with high dose group, ELD: *Caralluma tuberculata* extract low dose, EMD: *Caralluma tuberculata* extract medium dose, EHD: *Caralluma tuberculata* extract high dose, SD: Vitamin C group. Data are means  $\pm$  S.D. of n=3 per group. Different letters (a-f) on each mice group represent significance at  $p < 0.001$ .



ance (ANOVA) and Tukey test using GraphPad Prism 5 for windows.

## RESULTS

### Effect on body weight

Paracetamol administration to the mice at the dose of 200 mg/kg body weight showed increased levels of total cholesterol, triglycerides and ALT while decreased levels were noticed HDL as shown in Fig. 1. Similar findings have been reported by (Oyagemi & Odetola, 2010); that paracetamol significantly increased the levels of total cholesterol, triglyceride and ALT, and reduced HDL level further confirmed by Zakaria and others (Zakaria *et al.*, 2020). From Fig. 1 it can also be seen that walnut oil showed decreases in the level of cholesterol and ALT, while increasing the level of HDL. The cholesterol and Triglyceride levels were also decreased by vitamin C. It also increases the level of HDL. Furthermore, *C. tuberculata* decrease the levels of cholesterol, triglycerides and ALT and increase HDL level.

### Serum biochemical parameters

Estimation of different serum enzymes and markers has always been a useful quantitative and validated marker to assess liver injury and toxicity. In the current study, we have used different biochemical parameters as markers of liver damage and paracetamol-induced toxicity. As shown in Fig. 1, the levels of cholesterol, triglycerides, ALT, creatinine, and urea were significantly elevated in paracetamol-fed mice (positive control) compared to the negative control, indicating hepatic damage. However, pre-treatment with low, medium, and high doses of walnut oil and *C. tuberculata* extracts have significantly reduced these enzymes, almost to the level of normal values, especially on day 21. Of all these markers, ALT is the most common biochemical marker of liver toxicity. Following acute paracetamol toxicity, the level of ALT rose significantly reaching as high as 101±2.6 IU/L on day 21 compared to the negative control (60±1.0 IU/L). Pretreatment with high doses of both walnut oil (WHD group) and *C. tuberculata* extract (EHD group) had a significant impact on ALT levels, especially on day 21 when their levels were almost similar to the negative control group (63±1.0 IU/L for WHD group and 62±1.0 IU/L for HD group).

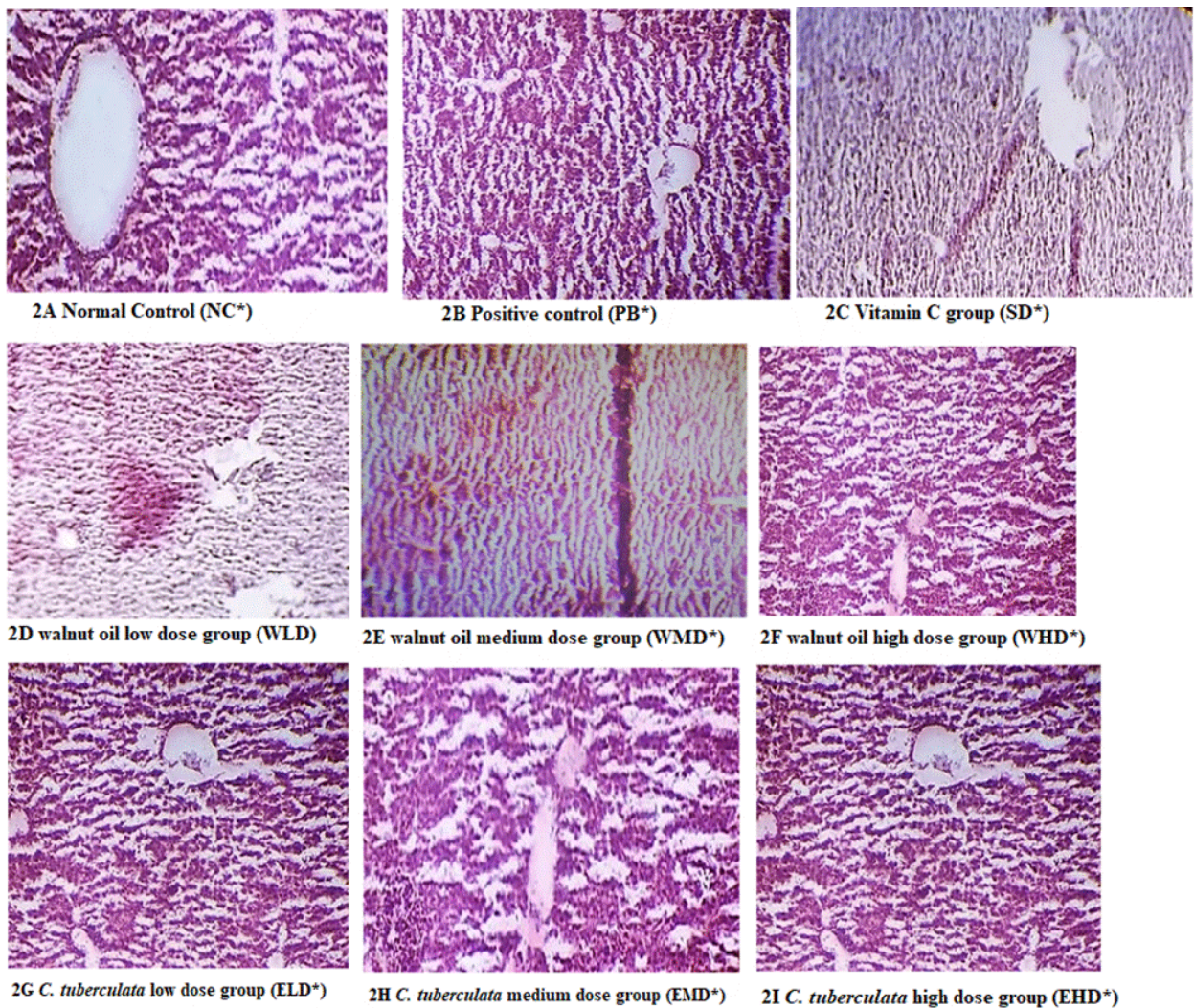
### Hematological parameters

Complete blood count including total leukocytes, neutrophils, lymphocytes, and platelets was also assessed on days 7, 14 and 21. Following acute paracetamol toxicity, the total leukocyte count remains nearly constant in negative controls (5.4×10<sup>9</sup> cells per liter) while in positive controls, a nearly 3-fold increase (14±5 10<sup>9</sup> cells per liter) was detected. Pretreatment with different doses of walnut oil and *C. tuberculata* extracts have attenuated the paracetamol toxic effects, bringing the leukocyte count to almost normal at day 21 as shown in Table 1. CBC also revealed that paracetamol toxicity results in elevated lymphocytes, but lower neutrophils count compared to the untreated negative control. Pretreatment has successfully reversed the effects of paracetamol toxicity in all doses, especially on day 21. The effect of different doses of Walnut Oil and *C. tuberculata* extracts on hematological parameters is summarized in Table 1.

Table 1. Hematological parameters of different mice groups from Day 7 to Day 21.

Groups	Total Leukocyte Count (x 10 <sup>9</sup> cells per liter)			Neutrophils (%)			Lymphocytes (%)			Platelets (x10 <sup>9</sup> /L)					
	Day 7	Day 14	Day 21	Day 7	Day 14	Day 21	Day 7	Day 14	Day 21	Day 7	Day 14	Day 21	Day 7	Day 14	Day 21
NC*	5.4±5a	5.4±5a	5.4±5a	10±0.15a	12±0.10a	13±0.2a	66±2.6a	65.33±2.a	63.67±1.5a	285±5a	286±7a	286±5a	285±5a	286±7a	286±5a
PC*	12.6±4.5b	12.8±4b	14±5b	8±0.1b	7±0.1b	6±0.1b	93.6±3.7b	97±2b	99.67±1.5b	195±4b	190±5b	185±4b	195±4b	190±5b	185±4b
WLD*	9.6±4.1c	8.4±2c	6±4c	7±0.1c	8±0.15c	9±0.2c	79.33±2.c	78.67±1.5c	73.6±2c	194±4.5b	198±5c	210±4.5c	194±4.5b	198±5c	210±4.5c
WMD*	9.6±5.5c	7±5d	4.2±5d	8±0.15b	10±0.2d	12±0.15d	84±1c	75±2c	68±1a	200±5c	210±6d	245±5.5d	200±5c	210±6d	245±5.5d
WHD*	7.4±5d	6.2±4e	3.4±5e	6±0.15d	11±0.15e	13±0.2a	80±3c	69±1c	66±1a	200±5d	235±5e	285±5a	200±5d	235±5e	285±5a
ELD*	9.6±4.5c	8.4±5c	5.9±4.5c	7±0.1c	10±0.0d	12±0.1d	91±2b	86±1d	77.33±1.5c	195±7.6b	197±5.5c	225±6e	195±7.6b	197±5.5c	225±6e
EMD*	7.3±5.5d	6.3±5f	4.1±5d	8±0.1b	11±0.15e	14±0.1e	79±2.6c	83.6±2d	76.6±2.5c	200±5d	234±5e	285±6.6a	200±5d	234±5e	285±6.6a
EHD*	6.8±5e	6.4±5f	5.4±5a	6±0.15d	13±0.15f	18±0.15f	92±2.6b	73±2.6c	63±2a	206±7e	245±7f	286±7f	206±7e	245±7f	286±7f
SD*	6.7±5e	6.1±2.5e	5.4±5.6a	7±0.1c	10±0.1d	13±0.1a	94±3b	74±1c	68.3±1.5a	206±5e	245±5f	286±6.1a	206±5e	245±5f	286±6.1a

NC: Normal Control, PC: positive control, WLD: walnut oil with low dose group, WMD: walnut oil with medium dose group, WHD: walnut oil with high dose group, ELD: *Caralluma tuberculata* extract low dose, EMD: *Caralluma tuberculata* extract medium dose, EHD: *Caralluma tuberculata* extract high dose, SD: Vitamin C group. Data are means ± SD of n = 3 per group. Different letters (a-f) on each mice group represent significance at p<0.001.



**Figure 2 (A–I). Histopathology of the mice liver samples**

NC: Normal Control, PC: positive control, WLD: walnut oil with low dose group, WMD: walnut oil with medium dose group, WHD: walnut oil with high dose group, ELD: *Caralluma tuberculata* extract low dose, EMD: *Caralluma tuberculata* extract medium dose, EHD: *Caralluma tuberculata* extract high dose, SD: Vitamin C group

### Liver Histopathology

Figure 2 (A–I) demonstrates the histopathological examination of liver sections from all experimental groups of mice. In the normal control group of mice (Fig. 2A), the liver parenchyma as well as endothelial linings of central veins had normal morphology with no evidence of pericentral fibrosis. Kupffer cells showed non-reactivity the orientation of the hepatic cord was well defined. Furthermore, the hepatic portal vein and artery showed normal structure with no signs of inflammation, necrosis, or fibrosis. In contrast, liver sections from paracetamol-treated mice (Fig. 2F) displayed visible signs of inflammation, necrosis, swelling of hepatocytes and mild steatosis despite no significant effect on liver parenchyma. Pretreatment with a low and medium dose of walnut oil had no significant impact on these parameters (Fig. 2D and E) while those treated with high doses (Fig. 2F) have normal liver parenchyma and hepatocytes and signs of inflammation. However, liver sections from mice treated with *C. tuberculata* extract, in all doses, have displayed normal liver parenchyma and hepatocytes with only mild inflammatory changes and necrosis (Fig. 2G–I) just like vitamin C treated mice (Fig. 2C).

### DISCUSSION

The current study aimed to investigate, the impacts of paracetamol on different biochemical and hematological parameters along with the histopathological study of the liver. Also, to study the roles of walnut oil and *C. tuberculata* against paracetamol-induced hepatotoxicity. In this study experimental animals (Mice) were divided into various groups. In these mice, hepato-toxicity was induced by paracetamol and then treated with walnut oil, *C. tuberculata* and vitamin C for 21 days.

In the present study, different biochemical parameters were studied. Paracetamol administration to the mice at the dose of 200 mg/kg body weight increased the levels of total cholesterol, triglycerides and ALT while decreased has occurred in the level of HDL. Similar findings have been reported; that paracetamol significantly increased the levels of total cholesterol, triglyceride and ALT, and reduced HDL level (Oyagbemi & Odetola, 2010). The same results have also been in agreement with (Zakaria *et al.*, 2020). There was an increase in the lipid profile by Intoxication with paracetamol in tissues and serum. An increase in the total cholesterol level



changes the function and structure of the membrane (Tatiya *et al.*, 2012). In the current study, walnut oil decreases the level of cholesterol and ALT, while increasing the level of HDL. The cholesterol and triglyceride levels were also decreased by vitamin C. It also increases the level of HDL and *C. tuberculata* decreases the levels of cholesterol, triglycerides and ALT and increases HDL level.

Administration of paracetamol produced a notable increase in the level of ALT enzyme and can demonstrate damage to the structural integrity of the liver. After cellular damage, it discharges into circulation which shows the onset of liver toxicity (Tatiya *et al.*, 2012). The serum ALT is the most important biochemical marker for the analysis of liver dysfunction (Mohammad *et al.*, 2022; Islam *et al.*, 2021; Mahmood *et al.*, 2014). ALT is an enzyme found in liver cells (hepatocytes). In the blood, it is leaked out where it is measured. Its level increases in acute liver toxicity like an overdose of paracetamol and viral hepatitis. Liver damage due to paracetamol is assessed by the increased level of ALT, when the liver is damaged it leaks out into the blood circulation (Ukpabigbo *et al.*, 2016). An elevated level of ALT after feeding the mice with paracetamol was also observed by (Gyawali *et al.*, 2017)

*C. tuberculata* is a succulent, angular, and leafless plant that flourishes in the wild (Sultan *et al.*, 2014). *Caralluma* is used as a hepatoprotective, anti-inflammatory, anti-ulcerogenic, anti-nociceptive and antioxidant (Kumar *et al.*, 2018). In the current study, *C. tuberculata* decrease the levels of total cholesterol, triglycerides and ALT and increase HDL level. This was also supported by Abdel-Sattar and others (Abdel-Sattar *et al.*, 2011) who observed that *C. tuberculata* not only reduced the levels of cholesterol and triglycerides but also increase the level of HDL. This study has also been an agreement with Poodineh and others (Poodineh *et al.*, 2016) that showed the protective effects of *C. tuberculata* that decrease the levels of ALT, TG and cholesterol while increasing the level of HDL. It also significantly decreases the levels of urea and creatinine in diabetic mice. The serum level of ALT is an indicator of liver function.

Walnut oil contains the largest concentration of polyunsaturated fatty acids (PUFA), which is up to 78% of the total fatty acids content as compared to other vegetable oils (Aye *et al.*, 2019; Shah *et al.*, 2014). In the present project, walnut oil decreases the level of cholesterol, TG and ALT, while increasing the level of HDL. Similar results have also been observed by Tariq and others (Tariq *et al.*, 2010). Walnut oil significantly reduces the levels of cholesterol, TG and rise in the level of HDL as observed by Zibaenezhad and others (Zibaenezhad *et al.*, 2017). The hepatoprotective effects of walnut against carbon tetrachloride (CCl<sub>4</sub>) induced liver toxicity was studied and it was found that walnut reduces the level of plasma enzymes that were raised by (CCl<sub>4</sub>). Damage to liver cells alters their membrane permeability and transport causing the leakage of enzymes from the cell (Eidi *et al.*, 2013). Walnut oil reduced the level of cholesterol was reported by that observed that walnut oil decrease cholesterol and it may be due to the polyunsaturated fatty acids content of walnut oil that caused a reduction in the synthesis of cholesterol or a result of phytosterols of walnut oil, which have structural similarity with cholesterol and thus decrease the serum cholesterol by inhibition of cholesterol absorption (Fink *et al.*, 2014).

The result from this study demonstrates that vitamin C reduced the level of total cholesterol, and tri-

glycerides while increasing the level of HDL, which is in contrast to the results of Eteng and others (Eteng *et al.*, 2006), that observed the effects of oral administration of vitamin C on lipid profile and serum of mice and it was found that vitamin C decreases total cholesterol but a non-significant increase in HDL. In the present study, vitamin C increases the level of HDL. The reason for this deviation might be the duration and dose of feeding and administration of walnut oil alone.

It was also noticed that there was a high level of creatinine in the paracetamol-fed group in comparison to the control group. It showed that paracetamol elevates the level of creatinine that was reduced by *C. tuberculata* and vitamin C as compared to walnut oil. The result was an agreement with previous studies which showed a rise in the level of serum creatinine after the administration of toxic doses of paracetamol (Mohammad *et al.*, 2022; Islam *et al.*, 2021; Mahmood *et al.*, 2014). An increase in the level of serum creatinine was also supported, as there was a rise in the creatinine level of the paracetamol-intoxicated group (Rosita *et al.*, 2018). The decrease in the level of creatinine by *C. tuberculata* was also observed by (Poodineh *et al.*, 2016). There was a considerable rise occurred in the level of urea in the paracetamol-fed group as compared to the control; walnut oil and vitamin C were more effective in curing the level of urea as compared to *C. tuberculata*. The same findings have also been reported that the serum urea level was significantly increased in the paracetamol-fed group (Gupta *et al.*, 2017). The increase in blood urea is associated with paracetamol-induced nephrotoxicity which has been confirmed that paracetamol elevates urea level and causes renal impairment (Hua *et al.*, 2018).

There was also a significant rise in TLC and lymphocyte counts and a drop in neutrophils, monocytes, eosinophils, and platelets count in the paracetamol-fed group as compared to the normal control group. The same results have also been reported that paracetamol produces a considerable increase in lymphocyte count and a drop in neutrophils, monocytes as well as eosinophils counts in paracetamol-induced liver toxicity in mice (Juma *et al.*, 2015). There was a significant deviation from the present results when hematological parameters were studied in paracetamol-fed mice and it was found that paracetamol caused no significant changes in lymphocytes, neutrophils, monocytes, eosinophils, and platelets count compared to their control group. The non-significant change of lymphocytes showed that the body's immune responses have not been compromised by paracetamol. The non-significant change in neutrophils showed that the ability of the body to destroy invading viruses, bacteria and other injurious agents has not been compromised by paracetamol. The non-significant change in monocytes indicates that the phagocytic function of the body has not been compromised, while the non-significant change in eosinophils count showed that the body's anti-allergic responses have not been compromised by paracetamol (Oyedemi *et al.*, 2013). In another study it was observed that liver damage produces by paracetamol caused drops in leucocytes, lymphocytes, and platelets count (Senthilkumar *et al.*, 2014). A previous study performed by Okokon and others (Okokon *et al.* 2017), of it, was studied that treatment of mice with paracetamol did not significantly affect the percentage of neutrophils but decreased the monocytes, lymphocytes, and eosinophils percentages.

## CONCLUSIONS

It was concluded from this study that there were positive effects of walnut oil and *C. tuberculata* extracts on the serum ALT values in all the treated groups. Elevation in serum ALT activities was found with paracetamol administration in mice. Walnut oil and *C. tuberculata* extract significantly reduced the serum ALT level when compared with normal and toxic control groups. In the present study lipid profile such as cholesterol, HDL, and TG levels, were also studied. Therefore, the curative effect of walnut oil and *C. tuberculata* extracts on serum lipid profile was investigated. A clear reduction was observed in mice administered with low and high doses of walnut oil and extract. Effects of walnut oil, *C. tuberculata* and vitamin C were similar as these normalized the serum lipid profile values. In the current study creatinine and urea levels were also studied. Paracetamol administration elevated the levels of creatinine and urea in experimental mice. Walnut oil and extract significantly reduced the levels of creatinine and urea when compared with a toxic positive control group.

In this some important hematological parameters like leucocytes, lymphocytes, neutrophils, monocytes, eosinophils, and platelets counts were investigated in paracetamol intoxicated mice. Oral administration of paracetamol caused a significant decrease in total neutrophils, monocytes, eosinophils, and platelets counts while increase in leucocytes and lymphocyte counts. Considerable changes were observed in hematological parameters with the administration of walnut oil, extract, and vitamin C. Based on the results obtained after the treatment of paracetamol intoxicated mice with walnut oil and *C. tuberculata* extracts, the following recommendation is given. Walnut oil and *C. tuberculata* extracts are hepatoprotective and renal-protective in nature. The walnut oil and extract are also beneficial and can be used as a remedy for cardiovascular diseases. The extract of walnut oil is also beneficial for some hematological parameters. *C. tuberculata* and walnut oil possess antioxidant properties, which could be used as the best source of advanced medication.

## Declarations

**Ethical Approval.** Ethical approval of the study was obtained from the ethics board of Islamia College University, Peshawar.

**Conflict of interest:** All the authors declare no conflict of interest.

## REFERENCES

- Abdel-Sattar E, Elberry AA, Harraz FM, Ghareib SA, Nagy AA, Gabr SA (2011a) Antihyperglycemic and hypolipidaemic effects of the methanolic extract of Saudi mistletoe (*Viscum schimperi* Engl.) *J Adv Res* 2: 171–177. <https://doi.org/10.1016/j.jare.2011.01.006>.
- Abdel-Sattar E, Harraz FM, Ghareib SA, Elberry AA, Gabr S, Suliman MI (2011b) Antihyperglycemic and hypolipidaemic effects of the methanolic extract of *Caralluma tuberculata* in streptozotocin-induced diabetic rats. *Nat Prod Res* 25: 1171–1179. <https://doi.org/10.1080/14786419.2010.490782>
- Adnan M, Jan S, Mussarat S, Tariq A, Begum S, Afroz A, Shinwari ZK (2014). A review on ethnobotany, phytochemistry and pharmacology of plant genus *Caralluma* R. *Br J Pharm Pharmacol* 66: 1351–1368. <http://dx.doi.org/10.1111/jphpp.12265>
- Arman M, Chowdhury KAA, Bari S, Khan MF, Huq MA, Haque A, Capasso R (2022) Hepatoprotective potential of selected medicinally important herbs: evidence from ethnomedicinal, toxicological and pharmacological evaluations. *Phytochem Rev* <https://doi.org/10.1007/s11101-022-09812-5>
- Baig MW, Ahmed M, Akhtar N, Okla MK, Nasir B, Haq IU, Al-Ghamdi J, Al-Qahtani WH, AbdElgawad H (2021) *Caralluma tuberculata* N.E.Br Manifests extraction medium reliant disparity in phytochemical and pharmacological analysis. *Molecules* 26: 7530. <http://dx.doi.org/10.3390/molecules26247530>
- Bhaargavi Y, Jyotsna GSL and Tripurana R (2014) A review on Hepatoprotective activity. *Int J Pharm Sci Res* 5: 690–702. [https://doi.org/10.13040/IJPSR.0975-8232.5\(3\).690-02](https://doi.org/10.13040/IJPSR.0975-8232.5(3).690-02)
- Bhattacharyya D, Pandit S, Mukherjee R, Das N, Sur TK (2003) Hepatoprotective effect of Himoliv, a polyherbal formulation in rats. *Indian J Physiol Pharmacol* 47: 435–440
- Britton MT, Leslie CA, Dandekar AM, McGranahan GH, Carboni E (2009) Persian Walnut. 285–300. <https://doi.org/10.1002/9781405181099.k0410>
- Carey AN, Fisher DR, Joseph JA, Shukitt-Hale B (2013) The ability of walnut extract and fatty acids to protect against the deleterious effects of oxidative stress and inflammation in hippocampal cells. *Nutr Neurosci* 16: 13–20. <https://doi.org/10.1179/1476830512Y.0000000023>
- Chandrasekharan NV, Dai H, Roos KL, Evanson NK, Tomsik J, Elton TS, Simmons DL (2002) COX-3, a cyclooxygenase-1 variant inhibited by acetaminophen and other analgesic/antipyretic drugs: cloning, structure, and expression. *Proc Natl Acad Sci U S A* 99: 13926–13931. <https://doi.org/10.1073/pnas.162468699>
- Delaviz H, Mohammadi J, Ghalamfarsa G, Mohammadi B, Farhadi N (2017) A review study on phytochemistry and pharmacology applications of *Juglans regia* plant. *Pharmacogn Rev* 11: 145–152. [https://dx.doi.org/10.4103/phrev.phrev.10\\_17](https://dx.doi.org/10.4103/phrev.phrev.10_17).
- Darbar S, Bhattacharya A, Chattopadhyay SJ (2011) Antihepatoprotective potential of livina, a polyherbal preparation on paracetamol induced hepatotoxicity: A comparison with silymarin. *Asian J Pharm Clin Res* 4: 72–77
- El-Hadary AE, Ramadan Hassanien MF (2016) Hepatoprotective effect of cold-pressed *Syzygium aromaticum* oil against carbon tetrachloride (CCl<sub>4</sub>)-induced hepatotoxicity in rats. *Pharm Biol* 54: 1364–1372. <https://doi.org/10.3109/13880209.2015.1078381>
- Eidi A, Moghadam JZ, Mortazavi P, Rezazadeh S, Olamafar S (2013) Hepatoprotective effects of *Juglans regia* extract against CCl<sub>4</sub>-induced oxidative damage in rats. *Pharm Biol* 51: 558–565. <https://doi.org/10.3109/13880209.2012.749920>
- Eteng MU, Ibekwe HA, Amatey TE, Bassey BJ, Uboh FU, Owu DU (2006) Effect of vitamin C on serum lipids and electrolyte profile of albino Wistar rats. *Niger J Physiol Sci* 21: 15–19. <https://doi.org/10.4314/njps.v21i1-2.53928>
- Fink A, Rüfer CE, Le Grandois J, Roth A, Aoude-Werner D, Marchionni E, Bub A, Barth SW (2014) Dietary walnut oil modulates liver steatosis in the obese Zucker rat. *Eur J Nutr* 53: 645–660. <https://doi.org/10.1007/s00394-013-0573-z>
- Gupta G, Chellappan DK, Kikuchi IS, Pinto TJA, Pabreja K, Agrawal M, Singh Y, Tiwari J, Dua K (2017) Nephrotoxicity in rats exposed to paracetamol: The protective role of morabosteroid, a steroidal glycoside. *J Environ Pathol Toxicol Oncol* 36: 113–119. <https://doi.org/10.1615/JEnvironPatholToxicolOncol.2017019457>
- Hua H, Ge X, Wu M, Zhu C, Chen L, Yang G, Zhang Y, Huang S, Zhang A, Jia Z (2018) Rotenone protects against acetaminophen-induced kidney injury by attenuating oxidative stress and inflammation. *Kidney Blood Press Res* 43: 1297–1309. <https://doi.org/10.1159/000492589>
- Gagliano N, Grizzi F, Annoni G (2007) Mechanisms of aging and liver functions. *Dig Dis* 25: 118–123. <https://doi.org/10.1159/000099475>
- Gyawali R, Shrestha A, Khanal A, Pyakurel JS, Joshi N, Bajaj P, Chaudhary P, Thapa R (2017) Hepatoprotective properties of selected plants against paracetamol induced hepatotoxicity in mice. *J Inst Sci Tech* 22: 147–151. <https://doi.org/10.3126/jist.v22i1.17766>
- Hussain L, Ikram J, Rehman K, Tariq M, Ibrahim M, Akash MSH (2014) Hepatoprotective effects of *Malva sylvestris* L. against paracetamol-induced hepatotoxicity. *Turk J Biol* 38: 396–402. <http://dx.doi.org/10.3906/biy-1312-32>
- Islam MT, Quispe C, Islam MA, Ali ES, Saha S, Asha UH, Mondal M, Razis AFA, Sunusi U, Kamal RM, Kumar M, Sharifi-Rad J (2021) Effects of nerol on paracetamol-induced liver damage in Wistar albino rats. *Biomed Pharmacother* 140: 111732. <https://doi.org/10.1016/j.biopha.2021.111732>
- Juma KK, Maina SG, Muriithi JN, Mwangi BM, Mworia KJ, Mwonjoria MJ, Ngeranwa JN, Mburu ND (2015) Protective Effects of *Urtica dioica* and Cimetidine® on liver function following acetaminophen induced hepatotoxicity in mice. *J Develop Drugs* 4: 130. <https://doi.org/10.4172/2329-6631.1000130>
- Kannan N, Sakthivel KM, Guruvayoorappan C (2013) Protective effect of *Acacia nilotica* (L.) against acetaminophen-induced hepatocellular damage in wistar rats. *Adv Pharmacol Sci* 2013: 987692. <https://doi.org/10.1155/2013/987692>
- Kumar Bellamakondi P, Godavarthi A, Ibrahim M (2018) *Caralluma umbellata* Haw. protects liver against paracetamol toxicity and inhibits CYP2E1. *Bioimpacts* 8: 23–30. <https://doi.org/10.15171/bi.2018.04>
- Maev IV, Abdurakhmanov DT, Andreev DN, Dicheva DT (2014) Alcoholic liver disease: State-of-the-art. *Terapiticheski Arkhiv* 86: 108–116. <https://ter-arkhiv.ru/0040-3660/article/view/31527>

- Mahmood ND, Mamat SS, Kamisan FH, Yahya F, Kamarolzaman MF, Nasir N, Mohtarrudin N, Tohid SF, Zakaria ZA (2014) Amelioration of paracetamol-induced hepatotoxicity in rat by the administration of methanol extract of *Muntingia calabura* L. leaves. *Biomed Res Int* **2014**: 695678. <https://doi.org/10.1155/2014/695678>
- Mohamed Saleem TS, Madhusudhana Chetty C, Ramkanth S, Rajan VST, Mahesh Kumar K, Gauthaman K (2010) Hepatoprotective herbs – a review. *Int J Res Pharm Sci* **1**: 1–5
- Mollica A, Zengin G, Locatelli M, Stefanucci A, Macedonio G, Belagamba G, Onaolapo O, Onaolapo A, Azeez F, Ayileka A, Novelino E (2017) An assessment of the nutraceutical potential of *Juglans regia* L. leaf powder in diabetic rats. *Food Chem Toxicol* **107** (Pt B): 554–564. <https://doi.org/10.1016/j.fct.2017.03.056>
- Motwani H, Gadhavi H, Mangukia N, Patel SK, Rawal RM, Solanki HA (2021) Hepatoprotective plants role in human health: A cross-kingdom review. *J Med Plants Stud* **9**: 41–51. <https://doi.org/10.22271/plants.2021.v9.i3a.1292>
- Mudrikah, Bibi Y, Zahara K, Bashir T, Haider S (2015) Ethnomedicinal and pharmacological properties of *Caralluma tuberculata* N E Brown – A review. *Pure Appl Biol* **4**: 503–510. <http://dx.doi.org/10.19045/bspab.2015.44008>
- Kannan N, Sakthivel KM, Guruvayoorappan C (2013) Protective effect of *Acaia nilotica* (L.) against acetaminophen-induced hepatocellular damage in wistar rats. *Adv Pharmacol Sci* **2013**: 987692. <https://doi.org/10.1155/2013/987692>
- Omotayo MA, Ogundare OC, Longe AO, Adenekan S (2015) Hepatoprotective effect of *Mangifera-indica* stem bark extracts on paracetamol-induced oxidative stress in albino rats. *Eur Sci J* **11**. <https://ejournal.org/index.php/esj/article/view/6118>
- Okokon JE, Simeon JO, Umoh EE (2017) Hepatoprotective activity of the extract of *Homalium letestui* stem against paracetamol-induced liver injury. *Avicenna J Phytomed* **7**: 27–36
- Oyedede KO, Bolarinwa AF, Adabaniya RB (2013) Evaluation of hematological and reproductive effect of paracetamol (Acetaminophen) in female albino rats. *OSR J Dental Med Sci (IOSR-JDMS)* **3**: 72–75. <https://www.iosrjournals.org/iosr-jdms/papers/Vol3-issue5/Q0357275.pdf>
- Ouassou H, Bouhrim M, Daoudi NE, Mekhfi H, Ziyat A, Legssyer A, Aziz M, Bnouham M (2021) Evaluation of hepatoprotective activity of *Caralluma europaea* stem extract against CCl<sub>4</sub>-induced hepatic damage in wistar rats. *Adv Pharmacol Pharm Sci* **2021**: 8883040. <https://doi.org/10.1155/2021/8883040>
- Oyagbemi AA, Odetola AA (2010) Hepatoprotective effects of ethanolic extract of *Cnidiosolus aconitifolius* on paracetamol-induced hepatic damage in rats. *Pak J Biol Sci* **13**: 164–169. <https://doi.org/10.3923/pjbs.2010.164.169>
- Pathan MM, Khan MA, Somkuwar AP, Gaikwad NZ (2014) Hepatoprotective activity of maytenus emarginata against paracetamol-induced liver injury in male Wistar rats. *Int. J Pharm and Pharmaceut Sci* **6**: 320–323. <https://innovareacademics.in/journals/index.php/ijpps/article/view/2787>
- Pereira JA, Oliveira I, Sousa A, Valentão P, Andrade PB, Ferreira IC, Ferreres F, Bento A, Seabra R, Esteveinho L (2007) Walnut (*Juglans regia* L.) leaves: phenolic compounds, antibacterial activity and antioxidant potential of different cultivars. *Food Chem Toxicol* **45**: 2287–2295. <https://doi.org/10.1016/j.fct.2007.06.004>
- Panth N, Paudel KR, Karki R (2016) Phytochemical profile and biological activity of *Juglans regia*. *J Integr Med* **14**: 359–373. [https://doi.org/10.1016/S2095-4964\(16\)60274-1](https://doi.org/10.1016/S2095-4964(16)60274-1)
- Poodineh J, Alireza N (2016) Hypoglycemic and hypolipidemic effects of *Caralluma tuberculata* and its safety on liver and kidneys of diabetic rats. *Turkish J Biochem* **41**: 136–143 (in Turkish). <https://doi.org/10.1515/tjb-2016-0023>
- Qadir MI, Ali M, Saleem M, Hanif M (2014) Hepatoprotective activity of aqueous methanolic extract of *Viola odorata* against paracetamol-induced liver injury in mice. *Bangladesh J Pharmacol* **9**: 198–202.32. <https://doi.org/10.3329/bjp.v9i2.18049>
- Senthilkumar R, Chandran R, Parimelazhagan T (2014) Hepatoprotective effect of *Rhodiola imbricata* rhizome against paracetamol-induced liver toxicity in rats. *Saudi J Biol Sci* **21**: 409–416. <https://doi.org/10.1016/j.sjbs.2014.04.001>
- Real M, Barnhill MS, Higley C, Rosenberg J, Lewis JH (2019) Drug-induced liver injury: Highlights of the recent literature. *Drug Saf* **4**: 365–387. <https://doi.org/10.1007/s40264-018-0743-2>
- Rosita, Yuandani, Marianne (2018) Nephroprotective activity of ethanol extract of curcuma manga val in paracetamol induced male mice. *Asian J Pharma Clin Res* **11**: 126–128. <https://doi.org/10.22159/ajpcr.2018.v11s1.26585>
- Sami US, Javed IAK, Muhammad AK, Nadeem R, Mohammad MT, Zia ud D, Saadullah J (2019) Assessment of hepatoprotective activity of caralluma tuberculata stem against Ccl4-Induced liver damage in rabbits in Sherani District of Balochistan. *J Pharmacol Clin Res* **6**: 555697. <https://doi.org/10.19080/JPCR.2019.06.555697>
- Saleem M, Ahmed B, Karim M, Ahmed S, Ahmad M, Qadir MI, Syed N- i-H (2014) Hepatoprotective effect of aqueous methanolic extract of *Rumex dentatus* in paracetamol-induced hepatotoxicity in mice. *Bangladesh J Pharmacol* **9**: 284–289. <https://doi.org/10.3329/bjp.v9i3.18874>
- Shah TI, Sharma EA, Ahmad G (2014) *Juglans regia* Linn: A phytopharmacological review. *World J Pharm Sci* **2**: 364–373
- Stampar F, Solar A, Hudina M, Veberic R, Colaric MJ (2006) Traditional walnut liqueur – cocktail of phenolics. *Food Chem* **95**: 627–631. <https://doi.org/10.1016/j.foodchem.2005.01.035>
- Sultan K, Zakir M, Khan H, Khan IU, Rehman A, Akber NU, Muhammad N, Khan MA (2014) The effect of extract/fractions of *Caralluma tuberculata* on blood glucose levels and body weight in alloxan-induced diabetic rabbits. *J Evid Based Comp Altern Med* **19**: 195–199. <https://doi.org/10.1177/2156587214531019>
- Tariq M, Samina M, Zabta KS (2010) Molecular and morphological characterization of caralluma species. *Pak J Bot* **42**: 1163–1171
- Tatuya AU, Surana SJ, Sutar MP, Gamit NH (2012) Hepatoprotective effect of poly herbal formulation against various hepatotoxic agents in rats. *Pharmacognosy Res* **4**: 50–56. <https://doi.org/10.4103/0974-8490.91040>
- Tafere GG, Tuem KB, Gebre AK, Balasubramaniam R (2020) *In vitro* antioxidant and *in vivo* hepatoprotective activities of root bark extract and solvent fractions of *Croton macrostachyus* Hochst. Ex Del (Euphorbiaceae) on paracetamol-induced liver damage in mice. *J Exp Pharmacol* **12**: 301–311. <https://doi.org/10.2147/JEP.S259081>
- Ugwu CE, Suru SM (2021) Medicinal plants with hepatoprotective potentials against carbon tetrachloride-induced toxicity: a review. *Egypt Liver J* **11**: 88. <https://doi.org/10.1186/s43066-021-00161-0>
- Ukpabigbo U, Chigozie J, Monanu MO, Patrick C, Egbachukwu SI (2016) Potential hepatoprotective effect of different solvent fractions of *Ocimum gratissimum* (O.G) in a paracetamol induced hepatotoxicity in Wistar albino rats. *A J Physiol Biochem Pharmacol* **5**: 10–16. <https://doi.org/10.5455/jib.20160320033421>
- Ullah N (2017) Medicinal plants of Pakistan: Challenges and opportunities. *Int J Complement Alt Med* **6**: 00193. <https://doi.org/10.15406/ijcam.2017.06.00193>
- Waheed A, Barker J, Barton SJ, Khan GM, Najm-Us-Saqib Q, Hussain M, Ahmed S, Owen C, Carew MA (2011) Novel acylated steroidal glycosides from *Caralluma tuberculata* induce caspase-dependent apoptosis in cancer cells. *J Ethnopharmacol* **137**: 1189–1196. <http://dx.doi.org/10.1016/j.jep.2011.07.049>
- Wahid A, Hamed AN, Eltahir HM, Abouzeid MM (2016) Hepatoprotective activity of ethanolic extract of *Salix subserrata* against CCl<sub>4</sub>-induced chronic hepatotoxicity in rats. *BMC Complement Altern Med* **16**: 263. <https://doi.org/10.1186/s12906-016-1238-2>
- Zakaria ZA, Kamisan FH, Kek TL, Salleh MZ (2020) Hepatoprotective and antioxidant activities of *Dicranopteris linearis* leaf extract against paracetamol-induced liver intoxication in rats. *Pharm Biol* **58**: 478–489. <https://doi.org/10.1080/13880209.2020.1764058>
- Zibaenezhad MJ, Ghavipisheh M, Attar A, Aslani A (2017) Comparison of the effect of omega-3 supplements and fresh fish on lipid profile: a randomized, open-labeled trial. *Nutr Diabetes* **7**: 1. <https://doi.org/10.1038/s41387-017-0007-8>