

Evaluating the *in-vivo* effects of olive oil, soya bean oil, and vitamins against oxidized ghee toxicity

Khushnuma Saleema^{1†}, Tariq Aziz^{2†✉}, Ayaz Ali Khan^{3✉}, Ali Muhammad¹, Shafiq ur Rahman⁴, Metab Alharbi⁵, Abdulrahman Alshammari⁵ and Abdullah F. Alasmari⁵

¹Department of Zoology, Islamia College University, Peshawar, 25120, Pakistan; ²Department of Agriculture, University of Ioannina Arta 47100, Greece; ³Department of Biotechnology, University of Malakand, Chakdara, 18800, Pakistan; ⁴Department of Environmental Science, Shaheed Benazir Bhutto University, Sheringal Dir Upper, Pakistan; ⁵Department of Pharmacology and Toxicology, College of Pharmacy, King Saud University, P.O. Box 2455, Riyadh 11451, Saudi Arabia

The aim of this study was to examine the protective role of various lipids (olive and soya oil) and vitamin (E and C) against the toxicity of thermally oxidized ghee in rabbits. Vanaspati ghee was thermally oxidized on a hot plate at 100°C for ten consecutive hours, and the oxidized ghee was stored in a refrigerator at -20°C until administration. Thirty male rabbits were purchased as experimental animals at a local market and were divided into ten corresponding groups of three based on their body weight. The blood samples of 5 ml were collected on day 0, 7, and 14 of the experiment for the analysis of hematological and biochemical serum parameters. We observed that oxidized ghee significantly elevated ALT level by affecting liver hepatocytes. Furthermore, vitamin E rapidly decreased the ALT levels compared to vitamin C and other oils. The oxidized ghee caused a significant increase in cholesterol compared to the other groups. Vitamin E and C showed the best antioxidant activity and decreased cholesterol levels to normal. Histopathological examinations of the normal rabbits' liver sections revealed no significant histological abnormality. The liver of the rabbits fed with oxidized ghee had an intact lobular architecture but the portal tracts showed inflammation and mild fibrosis, the bile ducts showed proliferation, and the hepatocytes showed feathery degeneration. In the liver sections from the groups fed with oxidized ghee and different doses of olive oil inflammation in portal tracts and large vacuoles in the hepatocytes were observed. The group fed with oxidized ghee and vitamin E had intact lobular architecture with no significant histological abnormality in portal tracts but fatty changes were present in the hepatocytes. These findings support the antioxidant activity of vitamins C and E as they reduced liver infection caused by oxidized ghee. It was concluded that oxidized ghee was highly toxic and not safe for consumption. The present study indicated that soya bean oil and vitamin E were more effective in protecting against the toxicity of thermally oxidized ghee than olive oil and vitamin C.

Keywords: olive oil, soybean oil, vanaspati ghee, hepatotoxicity, ALT, AST

Received: 10 November, 2022; revised: 03 February, 2023; accepted: 26 February, 2023; available on-line: 10 May, 2023

✉e-mail: iwockd@gmail.com (TA); ayazkhan@uom.edu.pk (AAK)

Acknowledgments of Financial Support: The authors greatly acknowledge and express their gratitude to the Researchers Supporting Project number (RSP2023R462), King Saud University, Riyadh, Saudi Arabia

Abbreviations: ALT, alanine transaminase; HDL, high density lipoproteins; LDL, low density lipoprotein; TG, Triglycerides

INTRODUCTION

Vegetable oils and fats make up a significant portion of our daily diet. Lipids comprise triglycerides, cholesterol, and antioxidants, among others, and when subjected to cooking or heating can convert into oxidized compounds like hydroperoxides, epoxides, and hydroxides (Fatiha *et al.*, 2020; Zeb & Khan, 2019; Kamal *et al.*, 2003). The three above types of oxidized compounds produced during heating usually convert into other compounds; however, the hydroperoxides convert into a variety of oxidized products that have been documented to be toxic for humans; and some of them are deemed to contribute to liver cancer (Zeb & Mehmood., 2012). Lipids, react with reactive oxygen species in a process is known as lipid peroxidation, which proceeds by a free radical chain reaction mechanism enhancing the production of free radicals (Gutteridge 1995; Halliwell & Gutteridge 1990). Free radicals significantly contribute to developing diseases like diabetes, atherosclerosis, cancer, chronic inflammatory disorders, and neurodegenerative diseases (Mobin, 2012). Free radicals are usually neutralized by enzymes (superoxide dismutase, catalase, and glutathione peroxidase) and antioxidants (vitamin E, vitamin C, carotenes, flavonoids, glutathione, uric acid, and taurine) (Jadhav & Priyanka, 2016). The benefits of olive oil for human health have been well reported and documented in the literature. Olive oil comprises monounsaturated fatty acids, like oleic acid, vitamin E, and polyphenols, which have beneficial effects on cardiac health (Nocella *et al.*, 2018). Particular attention has been given to VOO (virgin olive oil) because it contains antioxidants such as lipophilic and hydrophilic phenols (Kiritsakis *et al.*, 2020). Olive oil also contains 3,4-dihydroxy phenyl ethanol, an antioxidant with antithrombotic action (Paiva *et al.*, 2017). Vitamins E and C are known antioxidants that prevent the harmful effect of free radicals (Chan & Alvin, 1993). The co-loading of antioxidant vitamins E and C in olive oil emulsions has shown to be effective in maintaining the peroxide values (Cuomo *et al.*, 2020). Soybean oil is the leading edible vegetable oil in the world and is usually consumed in partially hydrogenated forms (Cinelli *et al.*, 2020). It contains many aromatic compounds, such as eugenol, which have antioxidant properties; it is worth mentioning that this oil is also one of the richest sources of vitamin E (Applewhite, 1981; Lee & Shibamoto, 2000). Commonly known as hydrogenated vegetable oils, Vanaspati ghee and banaspati ghee are high in trans fats, are hazardous to health, contributing to diseases like cardiovas-

cular diseases, obesity, and cancer (Rusin & Krawczyk, 2011). Ghee, when heated up to 120°C, becomes oxidized and hazardous for health, and is known as thermally oxidized ghee (Iqbal, 2014). It has been reported that thermally oxidized ghee causes *in vivo* toxicity by increasing hydroperoxide production and decreasing the radical scavenging assay (RSA) value. Oxidized ghee's toxicity increases with the oxidation time, leading to hypertriglyceridemia, and increase in total cholesterol and LDL-cholesterol level (Zeb & Mehmood, 2012). As ghee is used to fry and cook food in our society, and persistently heated for a long time, hence, ghee oxidation occurs and its oxidative products, toxic to humans, accumulate in food. Therefore, in this study we describe the toxic effects of the heated ghee on a number of hematological and biochemical parameters and liver histology in rabbits. Moreover, a number of antioxidant oils and vitamins were used along with oxidized ghee to determine their effect against the ill effects of thermally oxidized ghee.

MATERIALS AND METHODS

Materials:

The Vanaspati ghee used in this research was from Halal Associated Industries Limited. The olive oil was packed and exported by Aceites Borges Pont, S.A.U, marketed in Pakistan by Zaitoon Pakistan (Pvt) Ltd, Islamabad, Pakistan. The soya bean oil utilized in this experiment was from Agro Processors and Atmospheric Gasses Pvt Ltd. The vitamin E: DL-alpha tocopherol acetate was from Merck Pharmaceuticals (Private Limited, 200 mg), and the Vitamin C was from Abbot Laboratories (Pak, 500 mg).

Thermal oxidation of ghee:

Vanaspati ghee was thermally oxidized on a hot plate at 100°C for ten consecutive hours, and oxidized ghee was stored in the refrigerator at -20°C until administration.

Experimental animals

Approval of the study was granted by Advanced Studies and Research Board and Ethical committee of Islamia College University, Peshawar, Pakistan. Rabbits were purchased from the dealers in Chakdara city and kept in the Bio-Park for two weeks. Green fodder and water were provided *ad libitum*. The experiments were conducted in the Biotechnology Department, University of Malakand, Chakdara, Dir (Lower), Khyber Pakhtunkhwa, Pakistan.

Experimental groups

After acclimatization, thirty rabbits were divided into ten replicate groups based on their body weight. Each group comprised three male rabbits. Group A (NC) served as negative control and was fed a regular diet. Group B (OG) was provided with oxidized ghee at the dose rate of 2 g per a kg of body weight. Group C was fed with oxidized ghee at the dose rate of 2 g/kg, and 1 g/kg of olive oil as an antioxidant. Group D was fed with oxidized ghee at 2 g/kg and an extra virgin olive oil at a dose rate of 2 g/kg body weight. Group E was fed with oxidized ghee at 2 g/kg, and 1 g/kg of soya bean oil. Group F was fed with oxidized ghee at 2 g/kg, and

2 g/kg of soya-bean oil. Group G was fed with oxidized ghee at 2 g/kg, and vitamin E at 100 mg/kg. Group H was fed with oxidized ghee at 2 g/kg and vitamin E at 200 mg/kg. Group I was fed with oxidized ghee at 2 g/kg, and vitamin C was given as an antioxidant at 100 mg/kg. Group J was fed with oxidized ghee at 2 g/kg with vitamin C as an antioxidant at 200 mg/kg.

Blood collection

The 5 ml blood samples were collected on experimental day, 0, 7, and 14, to analyze hematological and biochemical parameters of the serum. Strict aseptic conditions were applied during the blood sampling.

Hematological parameters

Three milliliters of the whole blood samples were transferred to heparinized tubes. A fully automated blood hematology analyzer (SYS MIX, Japan) was used to measure total red blood cells number, hemoglobin concentration, hematocrit value, mean corpuscular cell volume, mean corpuscular hemoglobin, mean corpuscular hemoglobin concentration, total leukocyte count, and neutrophils, eosinophils, lymphocytes, and platelets count.

Analysis of the biochemical parameters

Biochemical parameters of the serum were analyzed using total cholesterol and triglycerides test kits (Merck, Germany) and human HDL-c, LDL-c, ALT, and glucose assay kits (HUMAN Diagnostics, Germany).

Histopathology

The rabbits were sacrificed at the end of the experiment, and their livers were dissected and stored in a formalin solution as previously described in Ayaz and others (Ayaz *et al.*, 2017). Each animal's liver was washed in normal saline solution and cut into slices. The slices were embedded in paraffin after dehydration with 100% ethanol and fixation with 10% formalin. The slices were then cut into 4 to 5 micrometers thick sections and stained with hematoxylin-eosin (HE, M 7000 D, SWIFT, Japan). A light microscope was used to examine the sections, while a 1.3 MP digital camera placed atop the microscope was used to capture images.

Statistical Analysis

All the experimental points consisted of 3 different samples. Data were analyzed by one-way analysis of variance (ANOVA) using GraphPad Prism version 5.

RESULTS

Analysis of blood biochemical parameters

After 7 days of the experiment, rabbit blood samples were collected, and serum was isolated from the samples for biochemical measurements.

It was observed that oxidized ghee significantly elevated the ALT level, suggesting affecting liver hepatocytes. Vitamin E decreased ALT level to the greatest extent, as compared to vitamin C and other oils that were fed.

The oxidized ghee diet caused significant raise in cholesterol levels that was mitigated with vitamins C and E, olive oil and soybean oil. The groups fed with vitamin E and C showed the greatest improvement of cholesterol

Table 1. Biochemical parameters in the studied groups of rabbits measured on day 7 and day 14 of the treatment.

Groups	ALT (IU/L)		Cholesterol (mg/dl)		TG (mg/dl)		HDL (mg/dl)		LDL (mg/dl)		Glucose (mg/dl)	
	Day 7	Day 14	Day 7	Day 14	Day 7	Day 14	Day 7	Day 14	Day 7	Day 14	Day 7	Day 14
NC*	62±0.26a	62±1.0a	67±0.2 a	70±1.1a	60±2.1a	63±1.5a	48±1.8a	47±1.0a	21±1.8a	21±1.8a	113±1.0a	112±2.1a
OG* 2 gm/kg	118±0.15b	148±1.5b	121±0.26b	130±2.0b	112±1.6b	121±2.0b	30±1b	26±2.0b	92±1.5b	92±1.5b	124±2.1b	95±1.0b
OO 1 gm/kg	83±0.26c	81±2.1c	109±0.30c	111±2.1c	107±2.0b	103±2.2c	35±0.68b	37±2.0c	74±1.4c	74±1.4c	75±1.0c	61±2.2c
OO 2 gm/kg	80±0.25d	74±1.6d	115±0.15d	116±1.5d	104±3.0b	99±2.2d	40±c	42±1.6a	76±1.5d	76±1.5d	80±2.0c	71±1.3d
SO1 2 gm/kg	85±0.15e	80±2.5e	92±0.26e	100±1.7e	104±2.5b	100±2.2d	40±1c	42±1.8a	50±2.5e	49±1.6d	80±2.5c	66±2.1d
SO 2 gm/kg	75±0.25f	72±1.8d	89±0.31f	85±2.2f	85±2.1c	79±1.7e	42±2c	43±2.1a	47±1.6e	40±2.4e	105±1.5d	77±2.1e
Vitamin E 100 mg/kg	55±0.21g	53±1.5f	75±0.27g	69±1.1a	97±2.1d	93±1.8f	30±2.3b	31±1.9d	48±2e	38±0.85d	83±3.5c	94±1.3b
Vitamin E 200 mg/kg	51±0.31h	56±1.8f	71±0.30h	68±2.1a	89±1.0e	83±1.5e	32±1.3b	35±2.0c	40±2.0f	33±1.0f	88±2.1e	103±2.5f
Vitamin C 100 mg/kg	84±0.15i	86±1.0g	81±0.31i	76±2.0g	93±2.5d	88±1.5f	34±1.5b	36±1.5c	48±2.0e	47±1.0d	76±3.2c	85±2.0g
Vitamin C 200 mg/kg	73±0.35j	70±2.0d	76±0.3j	71±1.0a	75±2.0e	70±1.5g	37±2b	40±2.1c	39±1.0f	3±2.0f	102±1.0f	105±2.0f

OO, olive oil; SO, soya bean oil; NC, normal control; OG, oxidized ghee

level parameters, that were close to normal. A significant decrease in cholesterol level was observed also in the groups that were fed with olive oil and soya bean oil, but it still remained above the normal range.

As shown in Table 1, oxidized ghee significantly elevated the level of triglycerides in serum. Vitamin E and C significantly decreased the triglycerides' level increased by oxidized ghee. At day 14, no significant difference ($P<0.05$) was observed between the mean values of triglycerides' levels in soya bean oil (2 g/kg) and vitamin E 200 g/kg fed groups. There was also no significant difference ($P<0.05$) between vitamin E (100 mg/kg) and vitamin C (100 mg/kg) fed groups. The triglycerides' levels differed significantly ($P<0.05$) between the remaining experimental groups. Olive oil lowered the triglycerides' level, but to a smaller extent than other antioxidants tested.

Oxidized ghee significantly lowered HDL serum levels. Soya bean oil and olive oil counteracted this effect, increasing HDL level close to normal. Vitamin E and C also increased HDL level but still it was below normal. There was significant difference in HDL serum level among all the groups except vitamin E and C groups. Figure 1 demonstrates that oxidized ghee significantly increased LDL level. There was a significant decrease in LDL level in the groups that were fed with soya bean oil, vitamin E and C but still it was above the normal range. Olive oil also lowered LDL level, but its effect was weaker than other antioxidants.

Statistical significance of the comparison between the means in a row is denoted with letters: the same letter shows no significant difference between the means, while different letters represent a significant difference ($P<0.05$).

Effects on hematological parameters

Whole blood samples were analyzed for complete hematology for each of the groups. As shown in Table 2; at day 14, the groups fed with soya bean oil and vitamin E had increased TRBC, Hb, PCV, and MCH level compared to the ghee fed group. Vitamins E and C showed better antioxidant activity as compared to other oils in reference to MCHC. Oxidized ghee significantly elevated TLC and decreased neutrophil number whereas olive and soya bean oils counteracted this effect on neutrophils. In addition, soya bean oil significantly decreased lymphocytes count increased by the oxidized ghee. Soya bean oil and vitamin C significantly increased platelets count lowered by the oxidized ghee.

Liver histopathology

Histopathological examination of the rabbits' liver sections are demonstrated in Fig. 2. Hepatocytes of the Group A (normal control) revealed no significant histological abnormality (Fig. 2A–2B). Liver sections from the Groups B and C showed intact lobular architecture but the portal tracts showed inflammation and mild fibrosis. The bile ducts showed increased proliferation and the hepatocytes displayed feathery degeneration. (Fig. 2C–2D and 2E–2F). In the liver sections from Groups D to G; the portal tracts showed inflammation; and large vacuoles were present in the hepatocytes (Fig. 2G–2H to 2M–2N). The liver sections of rabbits in groups H and I showed intact lobular architecture with no significant histological abnormality in portal tracts but fatty changes in hepatocytes were present (Fig. 2O–2P and 2Q–2R). Liver sections of rabbits in Group J showed abnormalities similar to the rest of the non-normal control groups,

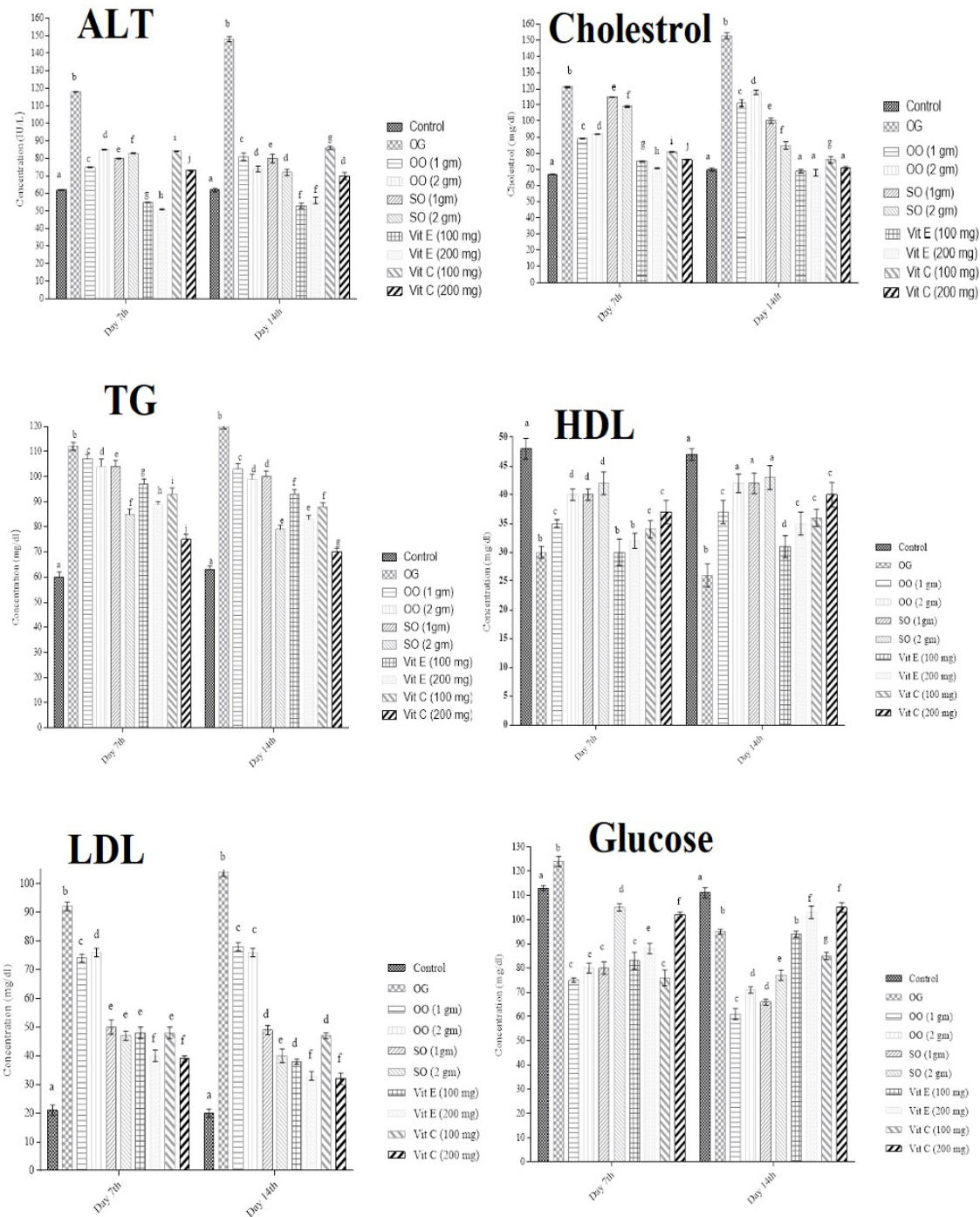


Figure 1. Hematological and biochemical parameters in the studied groups of rabbits at different timepoints.

Significant difference ($P < 0.05$) in glucose levels at day 14 was observed among all the groups, however, glucose levels were all in normal reference range in each group.

namely, sinusoidal dilation due to fats (Fig. 2S–2T). These findings revealed that vitamin E had superior antioxidant activity among the tested antioxidants because it effectively decreased liver inflammation caused by oxidized ghee.

Statistical significance of the comparison between the means in a row is denoted with letters: the same letter shows no significant difference between the means, while different letters represent a significant difference ($P < 0.05$).

DISCUSSION

This study showed that feeding rabbits with oxidized ghee at 2 g per kg body weight resulted in elevated ALT, triglycerides, total cholesterol and LDL levels, and overall decrease in HDL levels. Although this intervention decreased blood glucose levels, they remained in the reference range. These results corroborate similar recent study, where high triglycerides, cholesterol and LDL levels as well as low glucose level were observed in mice fed with heated ghee. Also, HDL level was low in ani-

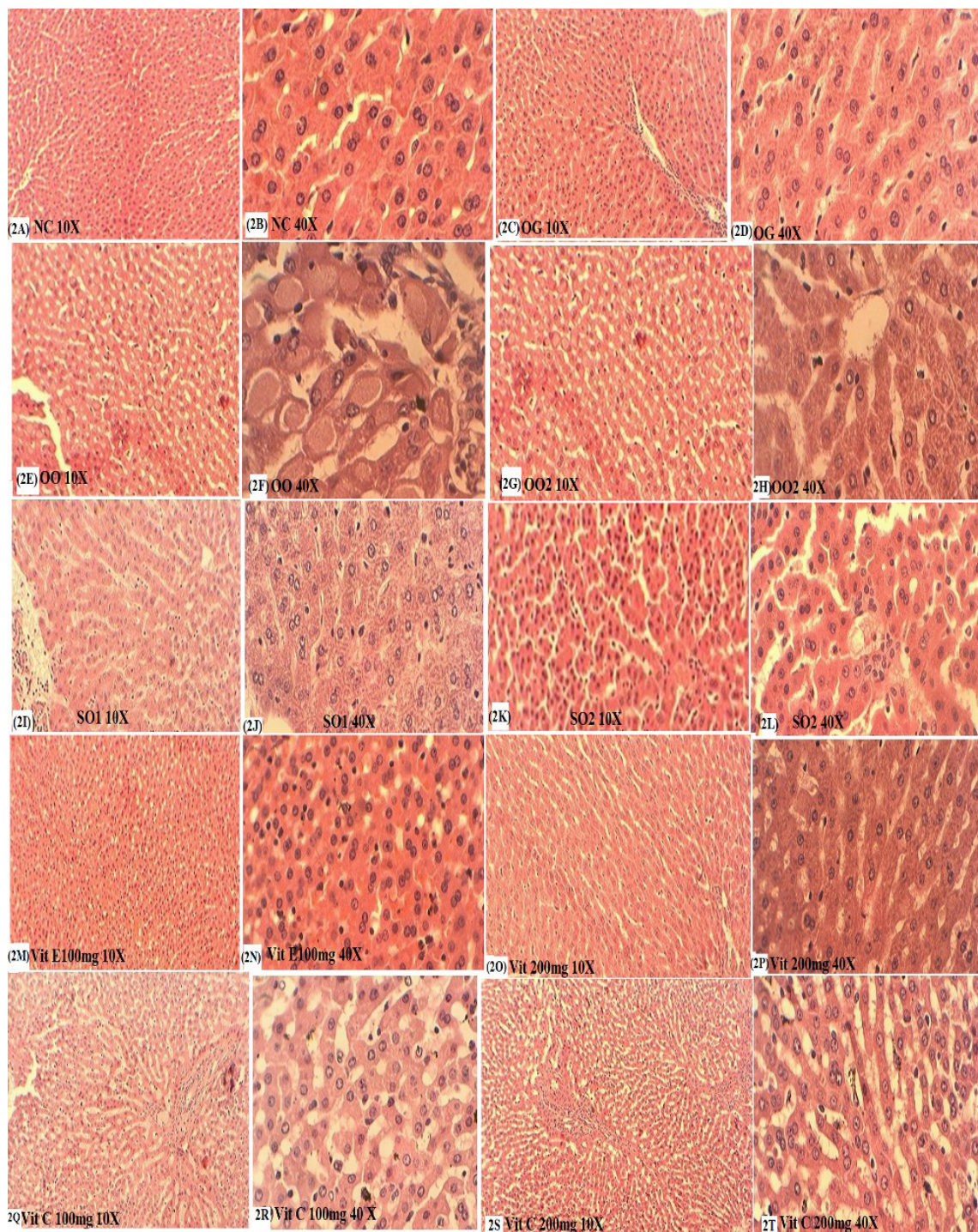


Figure 2. Histopathology of the rabbit liver samples

mals that were fed with thermally oxidized oils (Zahid *et al.*, 2022; Hina *et al.*, 2022; Sana *et al.*, 2022; Chinu & Rajamohan., 2011). Another study conducted in 2015 supports the findings of this study, i.e., high level of ALT, total cholesterol, triglycerol and LDL, as well as low glucose were observed in rabbits fed with oxidized corn oil (Aziz *et al.*, 2023; Uddin *et al.*, 2015). In the current paper, a decrease in TRBC, Hb, PCV, MCH, MCHC, neutrophils was observed in the rabbits fed with oxidized ghee. The platelets count was low but still in the normal range. Conversely, total leucocytes and lymphocytes numbers were increased above norm. When oxidized

ghee was fed to animals, it led to harmful effects on the blood cells (Sana *et al.*, 2022; Zeb & Ullah, 2015). Uddin and his coworkers (Uddin *et al.*, 2015) observed a decrease in TRB, hemoglobin, HCT, and an increase in WBC count in rabbits fed with oxidized corn oil. In the present study, it was observed that oxidized ghee was hepatotoxic and had adverse effect on liver histopathology. The liver tissue showed intact lobular architecture but the portal tracts showed inflammation and mild fibrosis, as well as accumulation of fat deposition in portal tract. The bile ducts showed signs of proliferation. The hepatocyte showed feathery degeneration. Similar results

Table 2. Hematology of different rabbits groups at 7th and 14th day.

Groups	RBC* (x 106/ μ l)		Hb* (%)		PCV* (%)		MCH* (pg)		MCHC* (gm/dl)		TLC* (103/ μ l)		N* (%)		L* (%)		PLT%	
	Day 7	Day 14	Day 7	Day 14	Day 7	Day 14	Day 7	Day 14	Day 7	Day 14	Day 7	Day 14	Day 7	Day 14	Day 7	Day 14	Day 7	Day 14
NC*	5.7 \pm 0.1a	5.6 \pm 0.21a	11 \pm 0.3a	12 \pm 0.2a	42 \pm 0.2a	44 \pm 2.5a	20.1 \pm 0.2a	21 \pm 1.5a	31.7 \pm 0.7a	33 \pm 1.5a	13.8 \pm 0.15a	13.8 \pm 0.32a	65.0 \pm 0.2a	65 \pm 2.1a	31.0 \pm 0.25a	34 \pm 3.0a	530 \pm 1.5a	535 \pm 1.0a
OG*2 gm/kg	4.1 \pm 0.15b	4.0 \pm 0.15	8.37 \pm 0.2b	8.1 \pm 0.2b	24 \pm 0.2b	23 \pm 2.0b	11 \pm 0.20b	10 \pm 2.0b	20 \pm 0.20b	19 \pm 1.5b	14.3 \pm 0.20a	14.3 \pm 0.15b	80.1 \pm 0.2b	30 \pm 2.5b	17.0 \pm 0.20b	67 \pm 2.5b	345 \pm 1b	330 \pm 2.0b
OO 1 gm/kg	4.6 \pm 0.15c	4.3 \pm 0.31	9.17 \pm 0.15b	9.0 \pm 0.1c	29 \pm 0.15c	27 \pm 2.0b	15 \pm 0.20c	14 \pm 2.1b	25.0 \pm 0.15c	22 \pm 2.1b	15.1 \pm 0.15b	15 \pm 0.25c	76.0 \pm 0.15c	43 \pm 1.5c	21.1 \pm 0.20c	56 \pm 2.5c	435 \pm 1.5c	429 \pm 1.5c
OO 2 gm/kg	4.33 \pm 0.15c	4.4 \pm 0.25	8.7 \pm 0.2b	8.5 \pm 0.1b	26 \pm 0.15d	25 \pm 1.0b	13.0 \pm 0.20d	11 \pm 2.5b	23.1 \pm 0.21d	22 \pm 2.1b	14.4 \pm 0.20a	15 \pm 0.15c	77.1 \pm 0.2d	45 \pm 1.5d	20.0 \pm 0.20d	52 \pm 2.1c	402 \pm 2.1d	400 \pm 1.5d
SO1 2 gm/kg	4.30 \pm 0.20c	4.5 \pm 0.10	8.7 \pm 0.2b	8.8 \pm 0.2c	26.0 \pm 0.2d	27 \pm 1.5b	13.1 \pm 0.21d	13 \pm 1.5a	23.0 \pm 0.25d	24 \pm 1.5b	13.4 \pm 0.25 a	14 \pm 0.25a	78 \pm 0.153e	56 \pm 2.0e	19.0 \pm 0.157e	42 \pm 2.1a	397 \pm 2.0e	386 \pm 1.5e
SO 2 gm/kg	5.57 \pm 0.15a	5.7 \pm 0.21a	10.9 \pm 0.21a	11 \pm 0.1d	42.1 \pm 0.21a	41 \pm 2.0a	20.0 \pm 0.25a	19 \pm 2.0	31.0 \pm 0.15a	30 \pm 1.6a	11.4 \pm 0.15c	12 \pm 0.15d	61 \pm 0.25f	58 \pm 2.5e	36.0 \pm 0.153f	40 \pm 3.5a	521 \pm 1.1f	516 \pm 1.5f
Vitamin E 100 mg/kg	4.57 \pm 0.15c	4.6 \pm 0.17	9.7 \pm 0.25b	9.9 \pm 0.1c	31 \pm 0.42e	33 \pm 1.5c	16.0 \pm 0.20e	19 \pm 2.5a	27.0 \pm 0.20e	28 \pm 2.5a	13.4 \pm 0.252a	14 \pm 0.21a	73.1 \pm 0.208g	34 \pm 2.6b	24.1 \pm 0.208g	63 \pm 2.5b	467 \pm 1.5g	450 \pm 2.0g
Vitamin E 200 mg/kg	5.10 \pm 0.20a	5.2 \pm 0.20a	10.4 \pm 0.2c	11 \pm 0.1d	40 \pm 0.40f	41 \pm 1.5a	19.1 \pm 0.21f	20 \pm 2.5a	29.0 \pm 0.20f	29 \pm 2.0a	15.2 \pm 0.1a	15 \pm 0.20c	68 \pm 0.20h	31 \pm 2.0b	29.0 \pm 0.153h	69 \pm 2.5c	496 \pm 1.5h	491 \pm 2.1h
Vitamin C 100 mg/kg	4.9 \pm 0.15c	4.9 \pm 0.25	8.1 \pm 0.2b	9.6 \pm 0.2c	22 \pm 0.25g	39 \pm 1.5a	11.0 \pm 0.20b	14 \pm 2.0c	18.1 \pm 0.21g	24 \pm 2.0b	10.1 \pm 0.1b	10 \pm 2.0d	82.1 \pm 0.208i	33 \pm 2.0b	15.0 \pm 0.15i	63 \pm 2.5b	317 \pm 1.5i	515 \pm 2.5i
Vitamin C 200 mg/kg	5.1 \pm 0.20a	5.1 \pm 0.15	8.67 \pm 0.25b	9.00 \pm 0.1c	26 \pm 0.20d	43 \pm 2.1a	13.1 \pm 0.21d	17 \pm 2.1a	21.0 \pm 0.25h	29 \pm 2.0a	15.1 \pm 0.25a	15 \pm 0.21c	78.1 \pm 0.2e	34 \pm 2.5b	19.1 \pm 0.20e	62 \pm 2.5c	394 \pm 2e	403 \pm 2.5d

OO, olive oil; SO, soya bean oil; NC, normal control; OG, oxidized ghee

were reported by Rahman and his team (Rahman *et al.*, 2012), in Long Evans rats, which showed scattered hepatocellular necrosis and degeneration of hepatocytes when fed with ghee (Zeb & Ullah, 2015; Rehman *et al.*, 2012).

The effect of olive oil and its high polyphenol contents have been studied before and the results support the present study's findings, i.e., increased HDL levels, decreased cholesterol, TG, and LDL levels in oxidized ghee fed rabbits (Covas *et al.*, 2006). However, our study's results are a little different from one of the earliest papers published in 1996 that stated that olive oil protects low-density lipoprotein from oxidative activities (Jassim *et al.*, 2010). It has also been observed that feeding of olive oil along with mercuric chloride gradually normalized serum ALT level (Wiserman *et al.*, 1996; Youcef *et al.*, 2014). Administration of olive oil appeared to decrease Hb concentration, WBC, platelet, and lymphocyte numbers in the treated rats, however, the difference was statistically significant only in the case of the platelet count (Nandakumaran *et al.*, 2014).

In the present study, rabbits fed with olive oil along with oxidized ghee had intact lobular architecture of the liver but their portal tracts showed inflammation and their hepatocytes contained large vacuoles. Szende and colleagues observed that olive oil reduced hepatotoxicity of oral carbon tetrachloride (CCl₄) (Szende *et al.*, 1994). Olive oil partially protected the liver from mercuric chloride (HgCl₂) induced damage. A prominent recovery in the form of normal hepatocytes and greatly reduced centrilobular necrosis were observed. Pronounced sinusoid with granular hepato-cytoplasm were also present (Nandakumaran *et al.*, 2014). Similar results were reported by another study in rats, in which the ingestion of olive oil protected the liver from ethanol-induced oxidative damage by affecting the cellular redox potential (Kasdal-lah *et al.*, 2008).

A significant mitigating effect against ghee-induced hepatotoxicity was observed for soya bean oil. This effect was dose dependent. One study showed that feeding rats with non-oxidized soya bean oil alone induced significant and dose-dependent alteration in biochemical and hematological parameters (Robaina *et al.*, 1995; Salahuddin *et al.*, 2013). Another study conducted using soybean oil showed that animals fed with the oil had changes in the liver, including distinct enlargement of central veins and erythrocyte accumulation, enlargement and congestion of sinusoids (Salahuddin *et al.*, 2013).

In the present study, we observed a protective role of vitamin E against the oxidized ghee-induced toxicity. Rabbits fed with oxidized ghee and vitamin E at 100 mg/kg or 200 mg/kg had decreased ALT, triglycerides, total cholesterol, and LDL levels, and increased HDL level in the direction of norm but still outside of the reference range. Similar results have previously been reported in case of mice fed with high fat diet and high-fat and high-cholesterol diet by increasing serum total triglycerides, cholesterol, and altered alanine aminotransferase, aspartate aminotransferase, and alkaline phosphatase (Liang *et al.*, 2021). It was also observed that vitamin E increased TRBC, Hb, PCV, MCH, MCHC, and neutrophil counts, and decreased TLC and lymphocyte count, but not to such an extent that these indicators were within the normal range. Amer and his research team also support these results showing that vitamin E and C reduce oxidative damage to RBC and platelets (Amer *et al.*, 1991).

In our study, the protective effect of vitamin E against oxidized ghee induced toxicity was also observed in the liver histopathology. An intact lobular architec-

ture with no significant histological abnormality in portal tracts was observed, however mild inflammation and mild fibrosis were detected in the portal tracts. These results are in agreement with the results of earlier studies which showed that vitamins E and C significantly improved liver fibrosis (Amer *et al.*, 2006). Also, vitamin C, when fed along with sodium fluoride (NaF) partially protected the liver from NaF toxicity (Stawiarska *et al.*, 2012). Uboh and his colleagues in 2012 demonstrated that in a model of gasoline vapor-induced liver injury in rats, vitamin E and C had protective effect on liver histopathology. The hepatoprotective effect was significantly higher in case of vitamin E than vitamin C (Uboh *et al.*, 2009). These findings support the results obtained in our study. In the previous studies, oxidized ghee caused inflammation and degeneration of hepatocytes (Zeb & Uddin 2017b), which is in concordance with our results. Also, both, enlargement of hepatic capillaries and severe liver necrosis were observed in the previous studies (Jimoh *et al.*, 2004). In our histopathological findings, we observed a protective role of olive oil, soybean oil, and vitamins E and C against the oxidized ghee effects, and only mild liver inflammation and fibrosis (groups that received antioxidants together with the oxidized ghee) were observed in oxidized ghee fed animals co-fed with these antioxidants.

CONCLUSIONS

The experiment presented here was designed to examine a protective role of various lipids (olive and soya oil) and vitamins (E and C) against thermally oxidized ghee toxicity in rabbits. Oxidized ghee diet altered the hematological and biochemical parameters and induced abnormalities in liver histopathology in rabbits. Soya bean oil and vitamin E were the most effective against the toxic effects of thermally oxidized ghee as compared to olive oil and Vitamin C. It is recommended that ghee can be substituted with soya bean oil. Further studies can be conducted to identify the oxidative products accumulated in oxidized ghee and test other antioxidants' potential against the toxic effects of the oxidized ghee.

Declarations

Conflict of interest: All the authors declare no conflict of interest.

REFERENCES

- Amer J, Ghoti H, Rachmilewitz E, Koren A, Levin C, Fibach E (2006) Red blood cells, platelets and polymorphonuclear neutrophils of patients with sickle cell disease exhibit oxidative stress that can be ameliorated by antioxidants. *Br J Hematol* **132**: 108–113. <https://doi.org/10.1111/j.1365-1412.2005.05834.x>
- Applewhite TH (1981) Nutritional effects of hydrogenated soya oil. *J American Oil Chem Soc* **58**: 260–269. <https://doi.org/10.1007/BF02582353>
- Aziz T, Ihsan F, Ali Khan A, Ur Rahman S, Zamani GY, Alharbi M, Alshammari A, Alasmari AF (2023) Assessing the pharmacological and biochemical effects of *Salvia hispanica* (Chia seed) against oxidized *Helianthus annuus* (sunflower) oil in selected animals. *Acta Biochim Pol* **27**. https://doi.org/10.18388/abp.2020_6621.
- Szende B, Timár F, Hargitai B (1994) Olive oil decreases liver damage in rats caused by carbon tetrachloride (CCl₄) *Exp Tox Pharmacol* **46**: 355–359. [https://doi.org/10.1016/S0940-2993\(11\)80116-8](https://doi.org/10.1016/S0940-2993(11)80116-8)
- Brahmi F, Haddad S, Bouamara K, Yalaoui-Guellal D, Prost-Camus E, de Barros JP, Prost M, Atanasov AG, Madani K, Boulekbache-Makhlouf L, Lizard G (2020) Comparison of chemical composition and biological activities of Algerian seed oils of *Pistacia lentiscus* L., *Opuntia ficus indica* (L.) mill. and *Argania spinosa* L. skeys. *Industrial Crops Products* **151**: 112456. <https://doi.org/10.1016/j.indcrop.2020.112456>
- Chan, AC (1993) Partners in defense, vitamin E and vitamin C. *Canadian J Physiol Pharmacol* **71**: 725–731. <https://doi.org/10.1139/y93-109>
- Chinu C, Rajamohan T (2011) Repeatedly heated cooking oils alter platelet functions in cholesterol fed Sprague Dawley rats. *Int J Biol Med Res* **2**: 991–997
- Covas MI, Nyyssönen K, Poulsen HE, Kaikkonen J, Zunft HJ, Kiesewetter H, Gaddi A, de la Torre R, Mursu J, Bäumlér H, Nascetti S, Salonen JT, Fitó M, Virtanen J, Marrugat J (2006) The effect of polyphenols in olive oil on heart disease risk factors: a randomized trial. *Ann Int Med* **145**: 333–341. <https://doi.org/10.7326/0003-4819-145-5-200609050-00006>
- Cuomo F, Cinelli G, Chirascu C, Marconi E, Lopez F (2020) Antioxidant effect of vitamins in olive oil emulsion. *colloids and interfaces*. **4**: 23. <https://doi.org/10.3390/colloids4020023>
- Friday, EU, Effiong, PE, Akpan, HD, Usho, IF (2012) Hepatoprotective effect of vitamins C and E against gasoline vapor-induced liver injury in male rats. *Turkish J Bio* **36**: 217–223. <https://doi.org/10.3906/biy-1004-111>
- Gutteridge JM (1995) Lipid peroxidation and antioxidants as biomarkers of tissue damage. *Clin Chem* **41**: 1819–1828
- Halliwel, B, Gutteridge JM (1990) Role of free radicals and catalytic metal ions in human disease: an overview. *Methods Enzymol* **186**: 1–85. [https://doi.org/10.1016/0076-6879\(90\)86093-b](https://doi.org/10.1016/0076-6879(90)86093-b)
- Iqbal MP (2014) Trans fatty acids – A risk factor for cardiovascular disease. *Pak J Med Sci* **30**: 194–197. <https://doi.org/10.12669/pjms.301.4525>
- Priyanka JM (2016) Ayurvedic perspective on oxidative stress management: *The Science of Free Radical Biology and Disease*. Armstrong D, Stratton RD eds, pp 483–492. <https://doi.org/10.1002/9781118832431.ch29>
- Jassim RA, Mihele D, Dogaru E (2010) Study regarding the influence of *Vitis vinifera* fruit (Muscat of Hamburg species) on some biochemical parameters. *FARMACLA* **58**: 332–340
- Kamal Eldin A, Mäkinen M, Lampi AM (2003) The challenging contribution of hydroperoxides to the lipid oxidation mechanism. Lipid oxidation pathways. *Swedish Univ Agri Sci* 1–36, Uppsala, Sweden
- Kasdallah-Grissa A, Nakbi A, Koubaa N, El-Fazaâ S, Gharbi N, Kamoun A, Hammami M (2008) Dietary virgin olive oil protects against lipid peroxidation and improves antioxidant status in the liver of rats chronically exposed to ethanol. *Nutr Res* **28**: 472–479. <https://doi.org/10.1016/j.nutres.2008.03.014>
- Khan AA, Zeb A, Shirazi STH (2017) Thermally oxidized olive oil produces biochemical, physiological effects and fatty liver in rats. *Chiang Mai J Sci* **44**: 847–857
- Kiritsakis, AK, Tsitsipas, CK (2020) A review of the evolution in the research of antioxidants in olives and olive oil during the last four decades. *J Food Bioactive* **11**. <https://doi.org/10.31665/JFB.2020.11236>
- Kosif, R, Yilmaz, F, Evrendilek, GA, Diramal, M (2010) Histopathological effects of Aloe barbadensis and soybean oil on rat liver. *Int J Morphol* **28**: 1101–1106. <http://dx.doi.org/10.4067/S0717-95022010000400019>
- Kumar MV, Sambaiah K, Lokesh BR (2000) Hypocholesterolemic effect of anhydrous milk fat ghee is mediated by increasing the secretion of biliary lipids. *J Nutrit Biochem* **11**: 69–75. [https://doi.org/10.1016/S0955-2863\(99\)00072-8](https://doi.org/10.1016/S0955-2863(99)00072-8)
- Lee KG, Shibamoto T (2000) Antioxidant properties of aroma compounds isolated from soybeans and mung beans. *J Agric Food Chem* **48**: 4290–4293. <https://doi.org/10.1021/jf000442u>
- Liang H, Jiang F, Cheng R, Luo Y, Wang J, Luo Z, Li M, Shen X, He F (2021) A high-fat diet and high-fat and high-cholesterol diet may affect glucose and lipid metabolism differentially through gut microbiota in mice. *Exp Anim* **70**: 73–83. <https://doi.org/10.1538/expanim.20-0094>
- Mobin J (2012) *Role of Reactive Oxygen Species in Normal Postnatal Lung Growth*. MSc. Thesis, University of Toronto (Canada) <https://hdl.handle.net/1807/33251>
- Moorkath N, Al-Sannan B, Al-Dossary M, Al-Shammari M (2014) Effect of olive oil administration on some hematologic and metabolic parameters in female rats. *Int J Pure Appl Biosci* **2**: 93–99
- Necib Y, Bahi A, Zerizer S, Abdennour C, Boulakoud MS (2014) Protective effect of virgin olive oil (*Olea europaea* L.) against oxidative damage induced by mercuric chloride in rat Albinos Wistar. *J Stress Physiol Biochem* **10**: 45–58
- Nocella C, Cammisotto V, Fianchini L, D'Amico A, Novo M, Castellani V, Stefanini L, Violi F, Carnevale R (2018) Extra virgin olive oil and cardiovascular diseases: benefits for human health. *endocrine, metabolic. Immune Disorders Drug Targets* **18**: 4–13. <https://doi.org/10.2174/1871530317666171114121533>
- Rahman MA, Jahan M, Karmaker S, Islam MK (2012) Effects of different fatty acid supplementation on body weight and hematobiochemical parameters in rat. *Int J Nat Sci* **2**: 21–25. <https://doi.org/10.13329/ijns.v2i1.10879>
- Robaina L, Izquierdo MS, Moyano FJ, Socorro J, Vergara JM, Montero D, Fernández-Palacios H (1995) Soybean and lupin seed meals as

- protein sources in diets for gilthead seabream (*Sparus aurata*): nutritional and histological implications. *Aquaculture* **130**: 219–233
- Rusin, A, Krawczyk, Z (2011) Genistein derivatization-from a dietary supplement to a pharmaceutical agent. In *Soybean and Health*, pp 253–282. <https://doi.org/10.5772/18733>
- Salahuddin, M, Sarker, M, Ahmad, N, Miah, MA (2013) Effects of varying concentration of soybean oils on hemato-biochemical profile in mice. *Bangladesh J Anim Sci* **42**: 148–151. <https://doi.org/10.3329/bjas.v42i2.18502>
- Sana, Ur Rahman S, Zahid M, Khan AA, Aziz T, Iqbal Z, Ali W, Khan FF, Jamil S, Shahzad M, Alharbi M, Alshammari A (2022) Hepatoprotective effects of walnut oil and *Caralluma tuberculata* against paracetamol in experimentally induced liver toxicity in mice. *Acta Biochim Pol* **69**: 871–878. https://doi.org/10.18388/abp.2020_6387
- Stawiarska-Pięta B, Bielec B, Birkner K, Birkner E (2012) The influence of vitamin E and methionine on the activity of enzymes and the morphological picture of liver of rats intoxicated with sodium fluoride. *Food Chem Toxicol* **50**: 972–978. <https://doi.org/10.1016/j.fct.2012.01.014>
- Uddin, MS, Sarker, MZI, Ferdosh, S, Akanda, MJH, Easmin, MS, Bt Shamsudin, SH, Yunus, KB (2015) Phytosterols and their extraction from various plant matrices using supercritical carbon dioxide: a review. *J Sci Food Agric* **95**: 1385–1394. <https://doi.org/10.1002/jsfa.6833>
- Uboh FE, Ekaidem IS, Eboang PE, Umoh IB (2009) The hepatoprotective effect of vitamin A against gasoline vapor toxicity in rats. *Gastroenterol Res* **2**: 162–167. <https://doi.org/10.4021/gr2009.06.1297>
- Wiseman, SA, Mathot JN, de Fouw NJ, Tijburg LB (1996) Dietary non-tocopherol antioxidants present in extra virgin olive oil increase the resistance of low-density lipoproteins to oxidation in rabbits. *Atherosclerosis* **120**: 15–23. [https://doi.org/10.1016/0021-9150\(95\)05656-4](https://doi.org/10.1016/0021-9150(95)05656-4)
- Wójcicki J, Różewicka L, Barcew-Wiszniowska B, Samochowiec L, Juźwiak S, Kadłubowska D, Tustanowski S, Juzyszyn Z (1991) Effect of selenium and vitamin E on the development of experimental atherosclerosis in rabbits. *Atherosclerosis* **87**: 9–16. [https://doi.org/10.1016/0021-9150\(91\)90227-t](https://doi.org/10.1016/0021-9150(91)90227-t)
- Necib Y, Bahi A, Zerizer S, Abdenmour C, Boulakoud MS (2014) Protective effect of virgin olive oil (*Olea europea* L.) against oxidative damage induced by mercuric chloride in rat Albinos Wistar. *J Stress Physiol Biochem* **10**: 45–58. <https://citeseerx.ist.psu.edu/document?repid=rep1&type=pdf&doi=de85afd8e76571d60913553a40eed96f51b82dcf>
- Zahid H, Shahab M, Ur Rahman S, Iqbal Z, Khan AA, Aziz T, Ali W, Zamani GY, Ahmad S, Shahzad M, Alharbi M, Alshammari A (2022) Assessing the effect of walnut (*Juglans regia*) and olive (*Olea europaea*) oil against the bacterial strains found in Gut Microbiome. *Progr Nutr* **27**: 1–13. <https://doi.org/10.23751/pn.v24i3.13311>
- Zeb A, Khan AA (2019) Improvement of serum biochemical parameters and hematological indices through α -Tocopherol administration in dietary oxidized olive oil induced toxicity in rats. *Front Nutr* **5**: 137. <https://doi.org/10.3389/fnut.2018.00137>
- Zeb A, Mehmood A (2012) Effects of oxidized vanaspati ghee on the serum lipids profile and radical scavenging activity of the *in vitro* lipids of liver, brain and muscles. *Turk Biyokimya Dergisi/Turkish J Biochem* **37**: 417–423. <https://doi.org/10.5505/tjb.2012.63325>
- Zeb A, Uddin I (2017) The coadministration of unoxidized and oxidized desi ghee ameliorates the toxic effects of thermally oxidized ghee in rabbits. *J Nutr Met* **2017**: 4078360. <https://doi.org/10.1155/2017/4078360>
- Zeb A, Ullah S (2015) Sea buckthorn seed oil protects against the oxidative stress produced by thermally oxidized lipids. *Food Chem* **186**: 6–12. <https://doi.org/10.1016/j.foodchem.2015.03.053>
- Zalejska-Fiolka J, Kasperczyk A, Kasperczyk S, Stawiarska-Pięta B, Fiolka R, Birkner E (2012) Influence of non-oxidised and oxidised rapeseed oil consumption on liver metabolism pathways and non-alcoholic steatohepatitis development in rabbits. *Bull Vet Inst Pulawy* **56**: 255–259. <https://doi.org/10.2478/v10213-012-0045-x>